

nordBLICK




SEHEN. KÖNNEN.

The unhappy pseudophakic patient: a new refractive opportunity with Sulcoflex Trifocal

ESCRS 2019 Paris
Detlef Holland

Rayner, Oculentis, Morcher, Ophthec, Alcon

Sulcoflex Trifocal



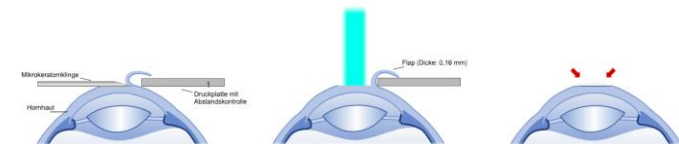
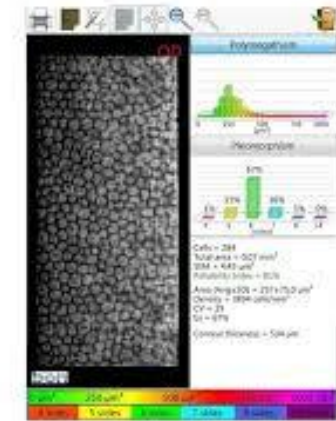
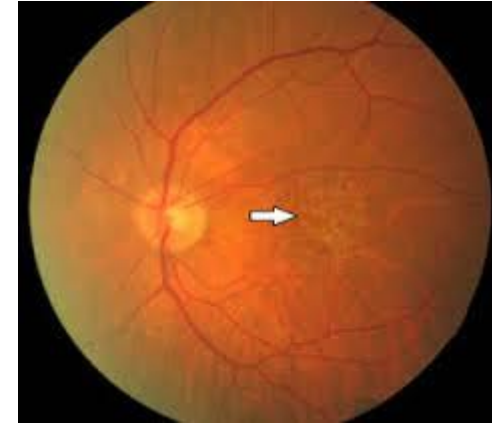
My indications for Sulcoflex Trifocal

- Pseudophakic patients with desire to become spectacle independent for near and intermediate distances
 - in Germany over 900,000 cataract surgery procedures per year
 - Due to perfect preoperative biometry most of the patients are emmetropic
 - But only 3% have a premium IOL
- Large number of patients who would benefit from this supplementary trifocal IOL



My indications for Sulcoflex Trifocal

- **Other interesting indications:**
 - Cataract patients who are not sure if a MIOL will make them happy, e.g. regarding mesopic phenomena. Night drivers!
 - Patients with moderate AMD.
 - Patients with moderate corneal pathology
 - Patients with previous refractive laser surgery
 - Patients with extreme refraction which may have higher risk for refractive surprise.
 - Patients with borderline pupil size.



Recruitment

- Important to look at the complete patient database, allows:
 - Higher standard of care
 - Bring back patients who need further treatment
 - Higher patient satisfaction
- Important to grow practices



Recruitment of patients



So sad...

We have a perfect tool but the patients do not know about it- Create awareness

Recruitment of patients



- How can we make our patients happy?

Recruitment...

- Share information with colleagues about the Sulcoflex Trifocal and good results.
- Share information from our staff to patients
 - E.g. asking pseudophakic patients who come for follow up if they are interested in higher levels of spectacle independence
- Marketing:
 - I do not believe in print media
 - Internet, Internet, Internet.....



Results European Multicenter Study

- Evaluation assessing visual quality and patient satisfaction after bilateral implantation of the Sulcoflex Trifocal in pseudophakic eyes.
- Exclusion criteria:
 - Corneal astigmatism ≥ 0.75 dpt
 - Irregular astigmatism
 - Corneal pathology
 - Glaucoma
 - Macular degeneration
 - Previous surgery

Prospective multicentre evaluation assessing visual acuity and patient satisfaction in pseudophakic patients with bilaterally implanted supplementary Trifocal intraocular lens.

Amon M, MD¹, Mularoni A, MD², Spedale F, MD³, Savaresi C, MD⁴,
Holland D, MD⁵, Jayaswal R, MD⁶, Domingues M, MD⁷

¹ Department of Ophthalmology, Academic Teaching Hospital of St. John, Vienna, Austria

² Department of Ophthalmology, State Hospital of the Republic of San Marino; San Marino

³ ASST, Franciacorta Chiari, Brescia, Italy

⁴ Humanitas San Pio X, Milan, Italy

⁵ Nordblick Augenzentrum Kiel GmbH, Germany

⁶ Laservision, Guildford, United Kingdom

⁷ Hospital Da Luz Clinica do Porto, Portugal

Corresponding author: S. Khokhar BSc Hons,
Head of Eye Science, Rayner, UK.

- Prospective
- 7 hospitals/7 surgeons
- 68 eyes/34 patients
- 5 patients/10 eyes in Kiel
- Pseudophakic eyes
- Bilateral implantation
- Follow up 1 month
- DVA, IVA, NVA
- Sc and cc
- Contrast visual acuity; F.A.C.T. Charts
- Defocus curve
- Spectacle independence
- Patient satisfaction

Prospective multicentre evaluation assessing visual acuity and patient satisfaction in pseudophakic patients with bilaterally implanted supplementary Trifocal intraocular lens.

Amon M, MD¹, Mularoni A, MD², Spedale F, MD³, Savaresi C, MD⁴,
Holland D, MD⁵, Jayaswal R, MD⁶, Domingues M, MD⁷

¹ Department of Ophthalmology, Academic Teaching Hospital of St John, Vienna, Austria

² Department of Ophthalmology, State Hospital of the Republic of San Marino, San Marino

³ ASST, Franciacorta Chiari, Brescia, Italy

⁴ Humanitas San Pio X, Milan, Italy

⁵ Nordblick Augenzentrum Kiel GmbH, Germany

⁶ Laservision, Guildford, United Kingdom

⁷ Hospital Da Luz Clinica do Porto, Portugal

Corresponding author: S. Khokhar BSc Hons,
Head of Eye Science, Rayner, UK.

Results- Refractive Outcome

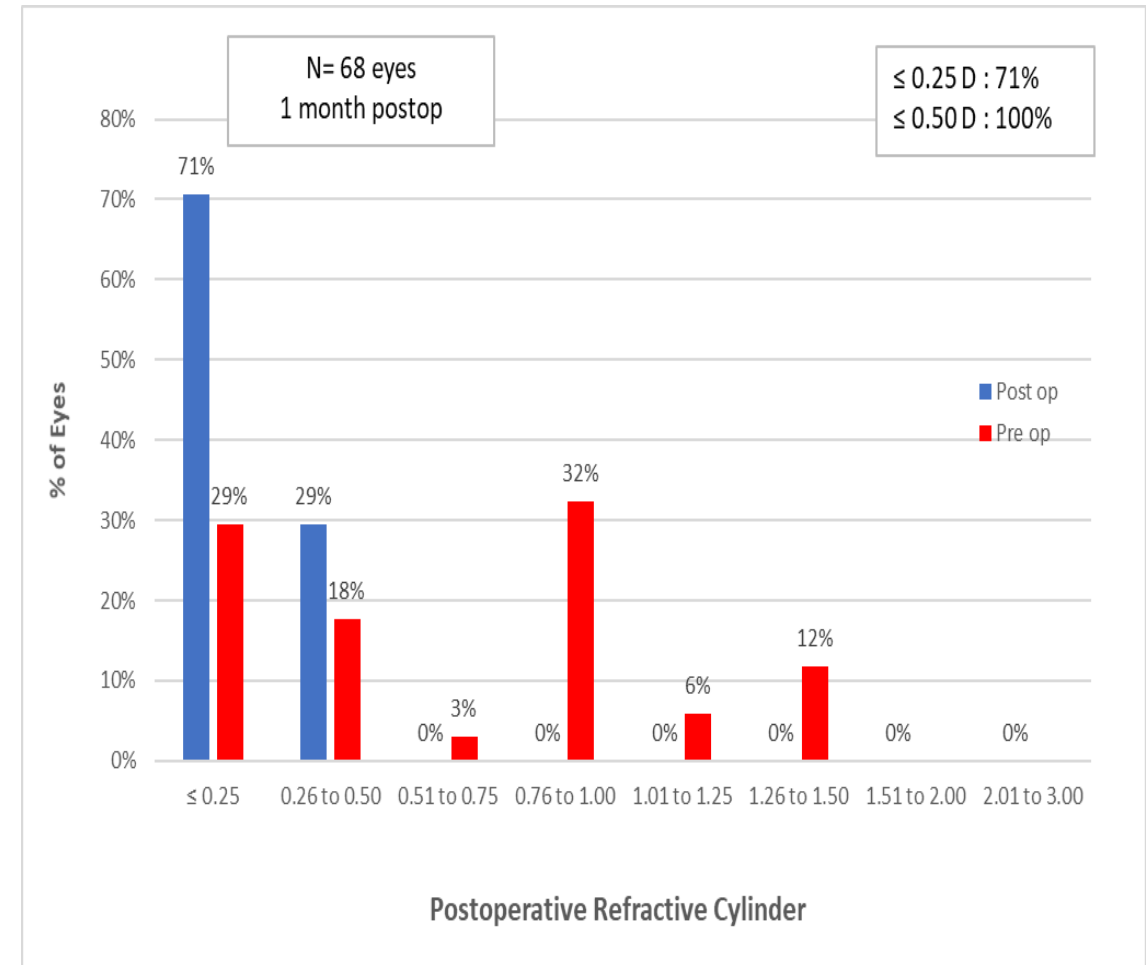
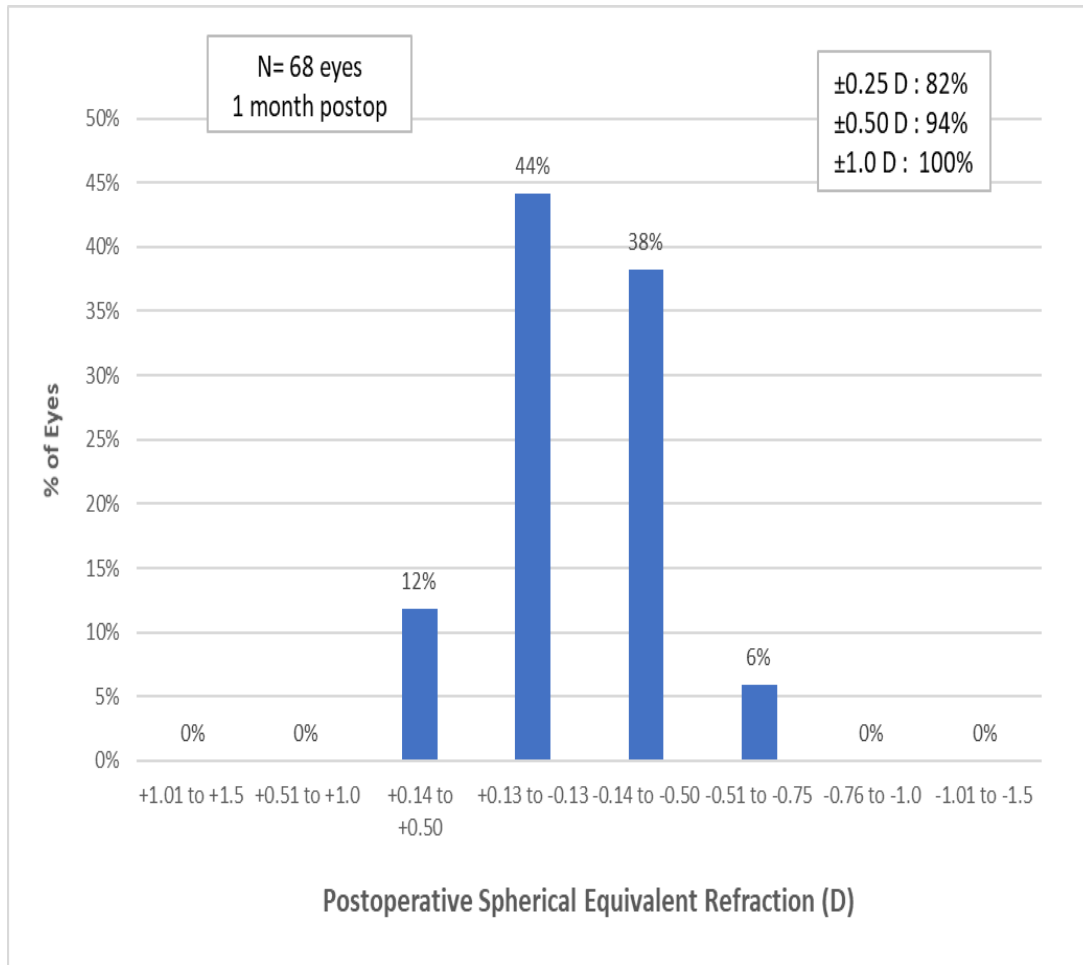
TABLE 1
Preoperative and Postoperative Characteristics
N=68

Characteristic	Preoperative	Postoperative
Age at time of surgery (y)		
Mean \pm SD	61.21 \pm 10.87	84% Monofocal
Range	43 to 81	16% Toric
Sphere (D)		
Mean \pm SD	0.31 \pm 1.13	-0.08 \pm 0.24
Range	-2.50 to 3.00	-0.50 to 0.50
Cylinder (D)		
Mean \pm SD	0.26 \pm 0.81	-0.16 \pm 0.24
Range	-1.50 to 1.50	-0.50 to 0.50
Spherical Equivalent (D)		
Mean \pm SD	0.39 \pm 1.27	-0.15 \pm 0.26
Range	-2.75 to 3.50	-0.75 to 0.25

D= diopters, SD= standard deviation. The Sulcoflex Trifocal 703F intraocular lens is manufactured by Rayner, Worthing, United Kingdom.

- All eyes are within ± 1.00 D and 94% within ± 0.50 D

Results- Subjective Refraction

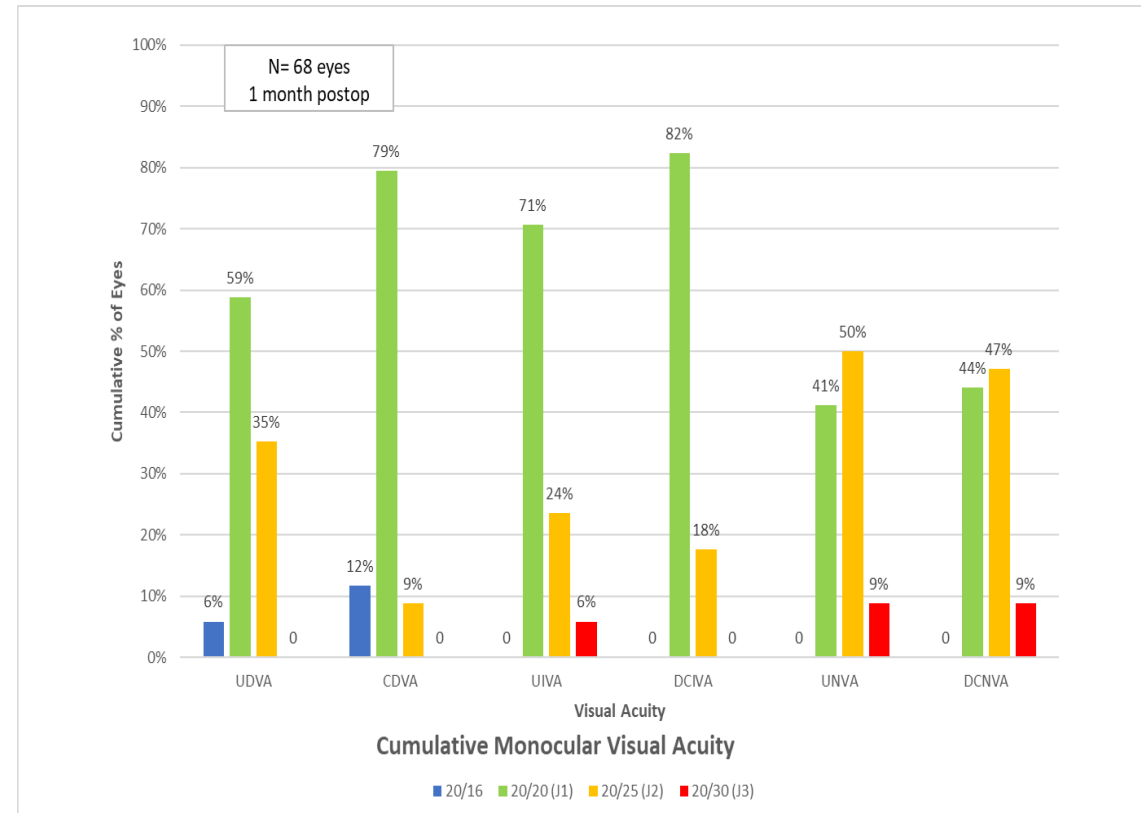


Results- Visual Acuity

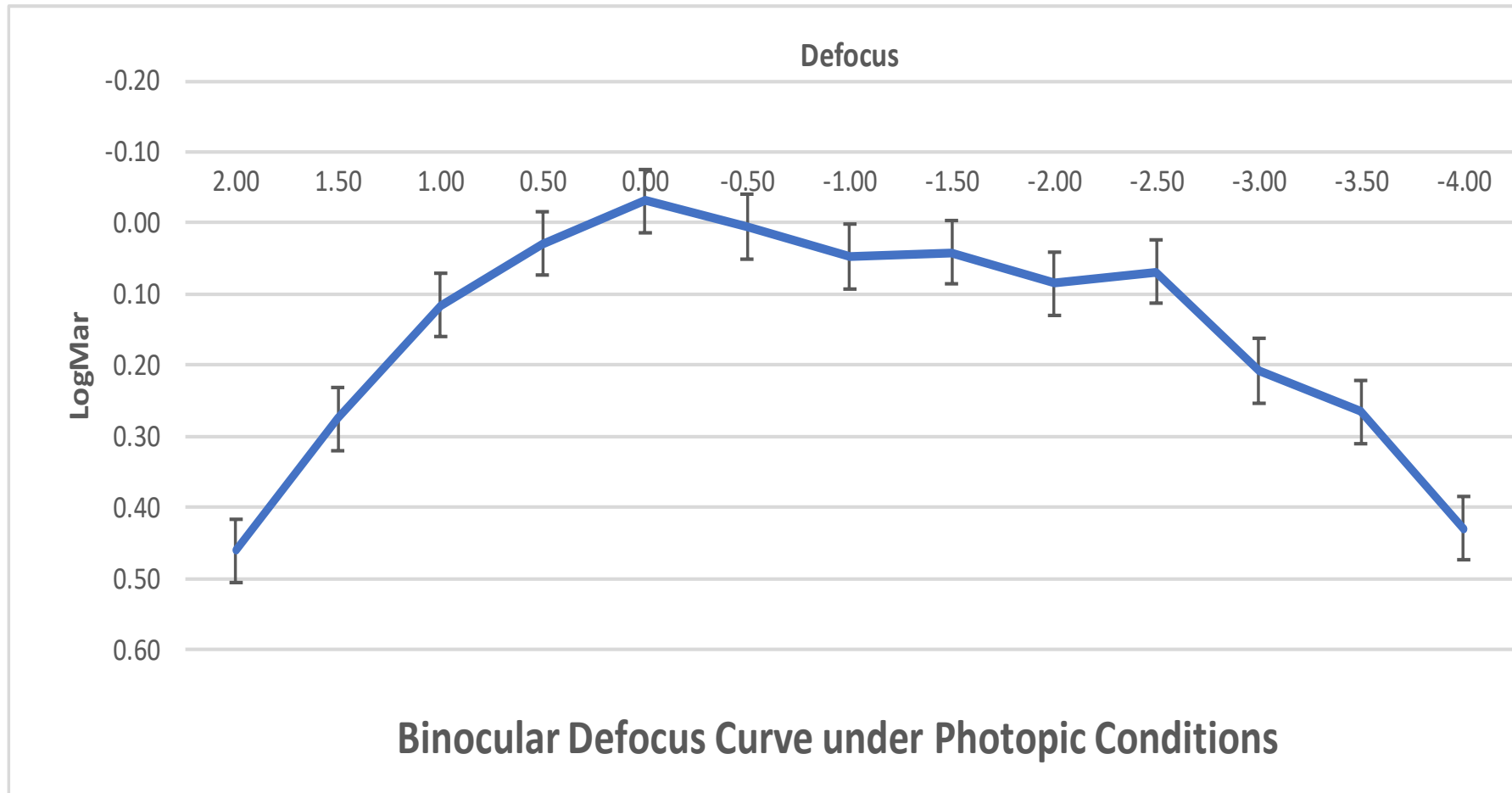
TABLE 2 Postoperative Visual Acuity N=68		
Visual Acuity	Monocular	Binocular
UDVA		
Mean ± SD	0.01 ± 0.04	-0.02 ± 0.04
Range	-0.10 to 0.00	-0.10 to 0.00
CDVA		
Mean ± SD	-0.01 ± 0.04	-0.03 ± 0.05
Range	-0.10 to 0.05	-0.10 to 0.00
UIVA		
Mean ± SD	0.03 ± 0.05	0.01 ± 0.03
Range	0.00 to 0.17	0.00 to 0.17
DCIVA		
Mean ± SD	0.01 ± 0.02	0.01 ± 0.02
Range	0.00 to 0.10	0.00 to 0.05
UNVA		
Mean ± SD	0.06 ± 0.06	0.05 ± 0.05
Range	0.00 to 0.18	0.00 to 0.18
DCNVA		
Mean ± SD	0.05 ± 0.06	0.04 ± 0.05
Range	0.00 to 0.18	0.00 to 0.10

*D= diopters, SD= standard deviation, UDVA= uncorrected distance visual acuity, CDVA= corrected distance visual acuity, UIVA= uncorrected intermediate visual acuity, DCIVA= distance corrected intermediate visual acuity, UNVA= uncorrected near visual acuity, DCNVA= distance corrected near visual acuity.
The Sulcoflex Trifocal 703F intraocular lens is manufactured by Rayner Intraocular Lenses Ltd, Worthing, United Kingdom.*

- All eyes achieved UDVA of 0.1 LogMAR or better,
- 94% of the patients reached monocular UIVA (70cm) of 0.1 LogMAR or better.
- 91% of the patients reached monocular UNVA (40cm) of 0.1 LogMAR or better.

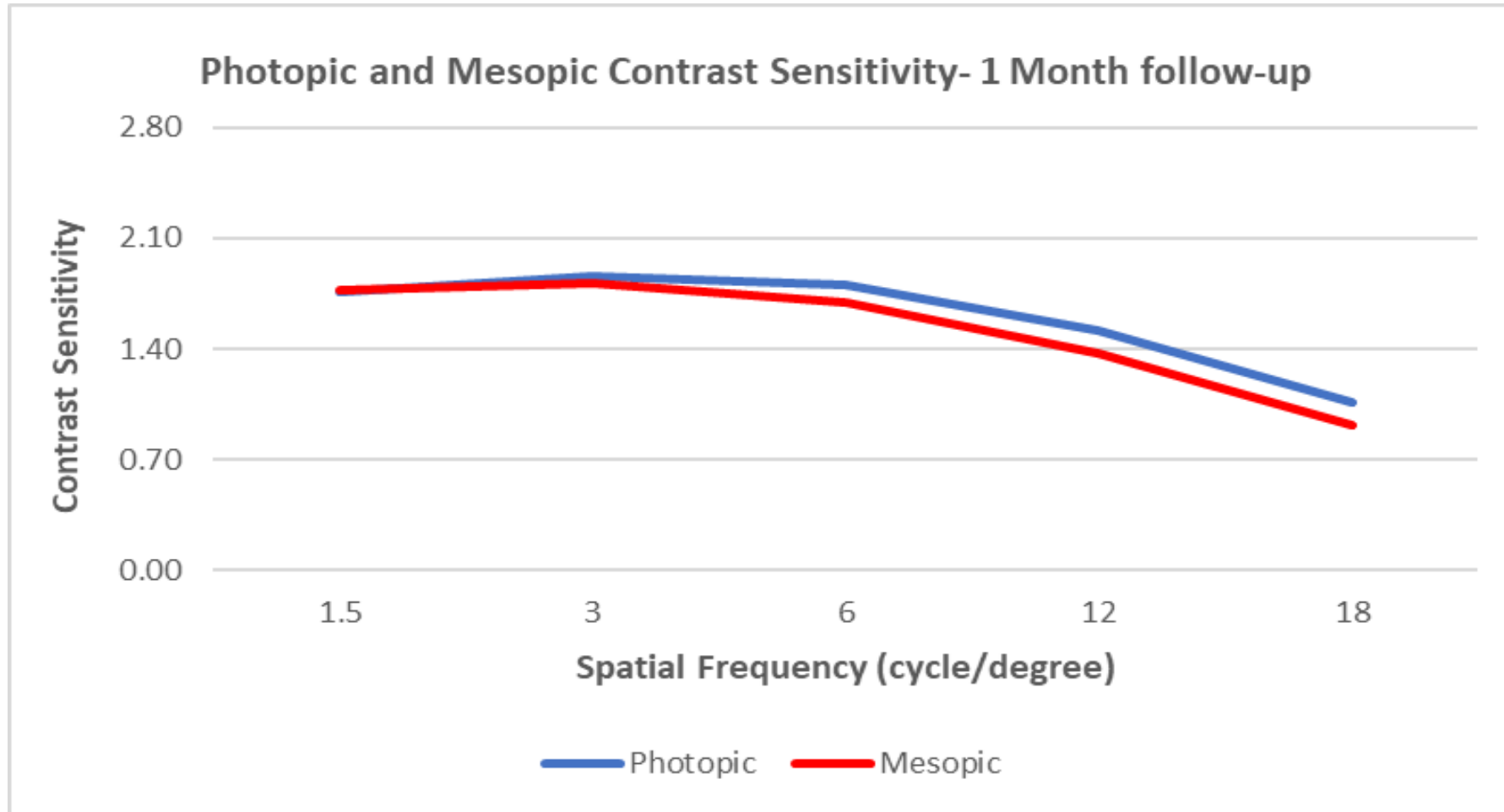


Defocus curve



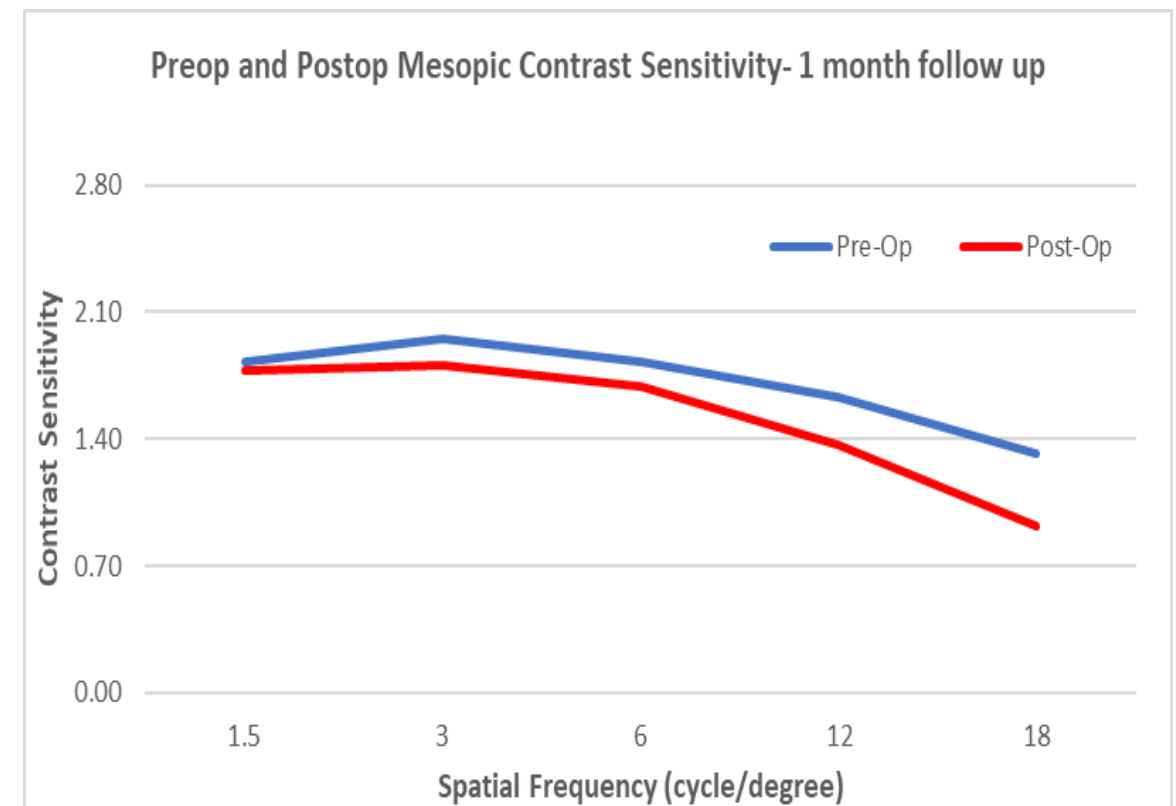
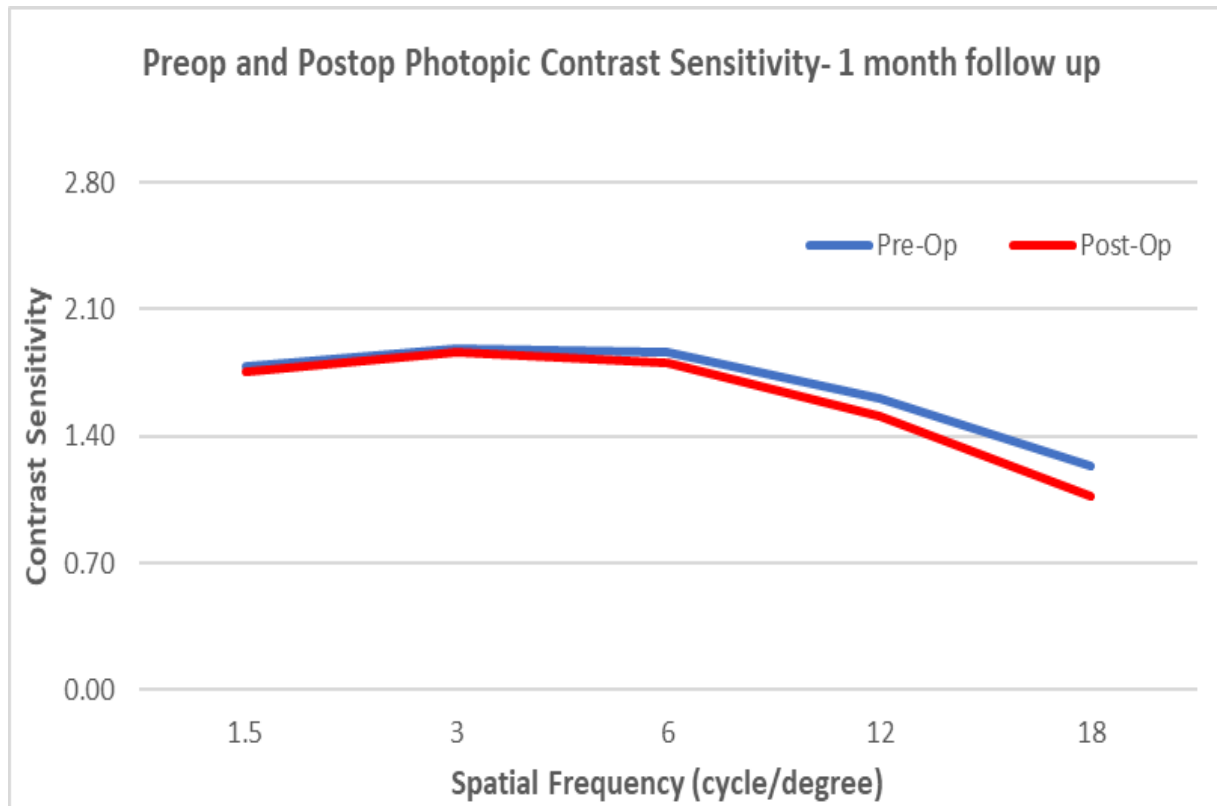
- At 1 month post-operatively, defocus curve showed a smooth transition phase between the far and the near focus.
- At -1.50 D, corresponding to near vision at 70 cm, visual acuity was on average 0.04 LogMAR
- At -2.50 D, corresponding to near vision at 40 cm, visual acuity was on average 0.07 LogMAR

Contrast Sensitivity Post-Op



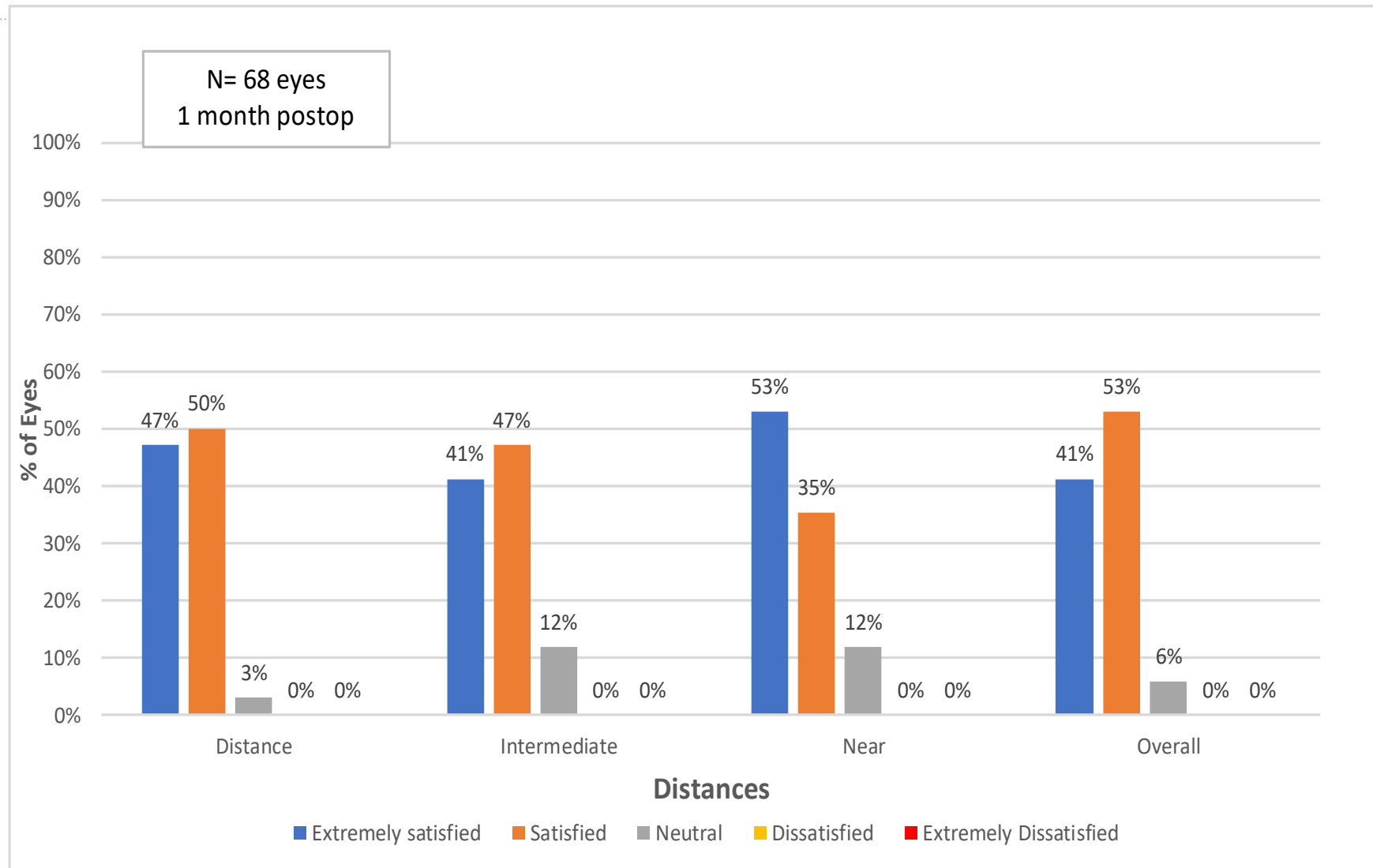
- After one month contrast sensitivity was within normal range in photopic conditions (85 cd/m²)-
- In higher spatial frequencies (> 6 cycle/degree) mesopic sensitivity was lower than photopic as expected.

Contrast Sensitivity Pre & Post-Op



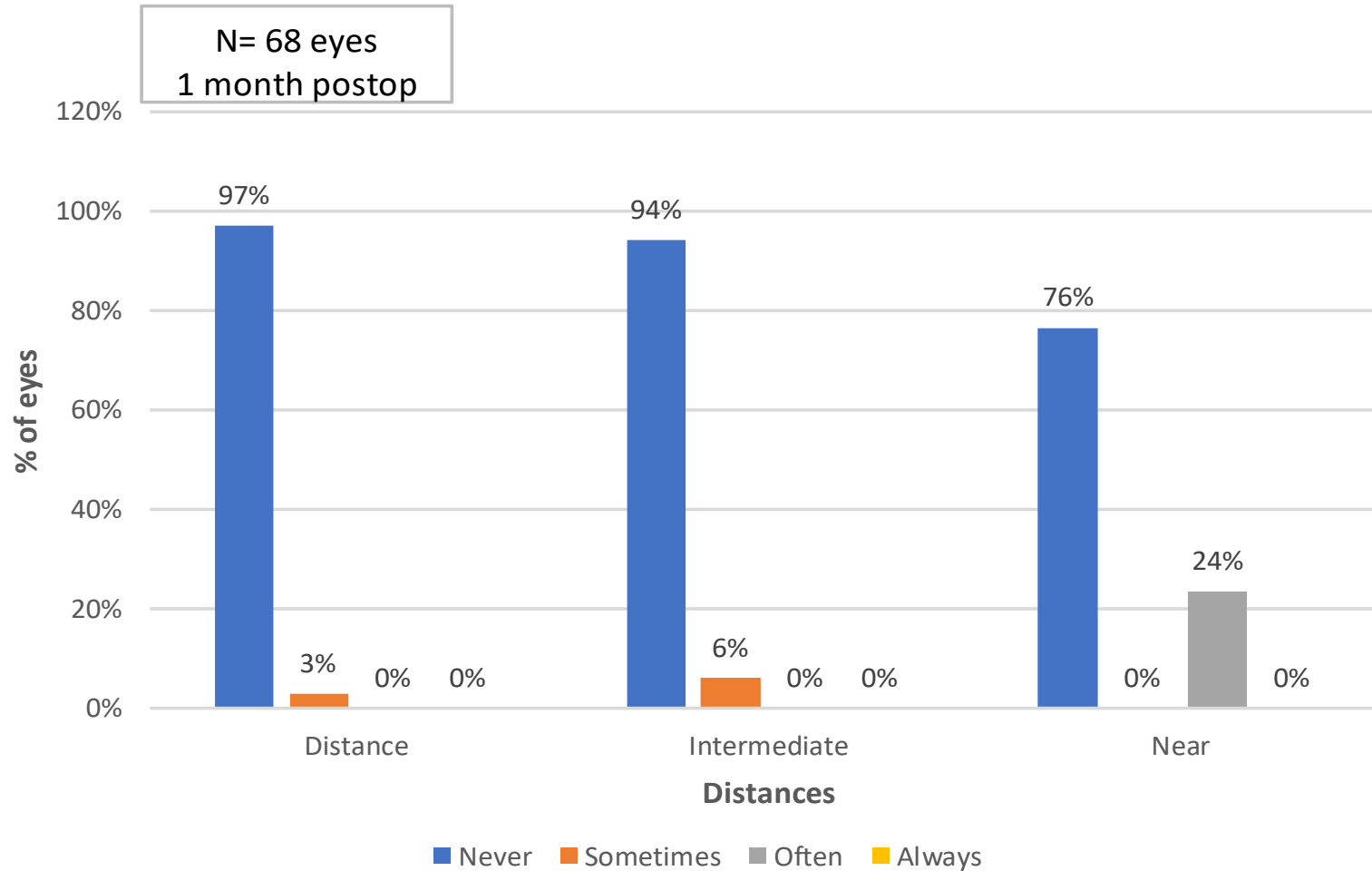
- Postoperatively contrast sensitivity was comparable to the pseudophakic eyes pre-op.
- Postoperatively mesopic sensitivity was lower than pre-op.

Patient Satisfaction



How satisfied are you with your visual quality in near, intermediate and far distance? (Likert Scale Score)

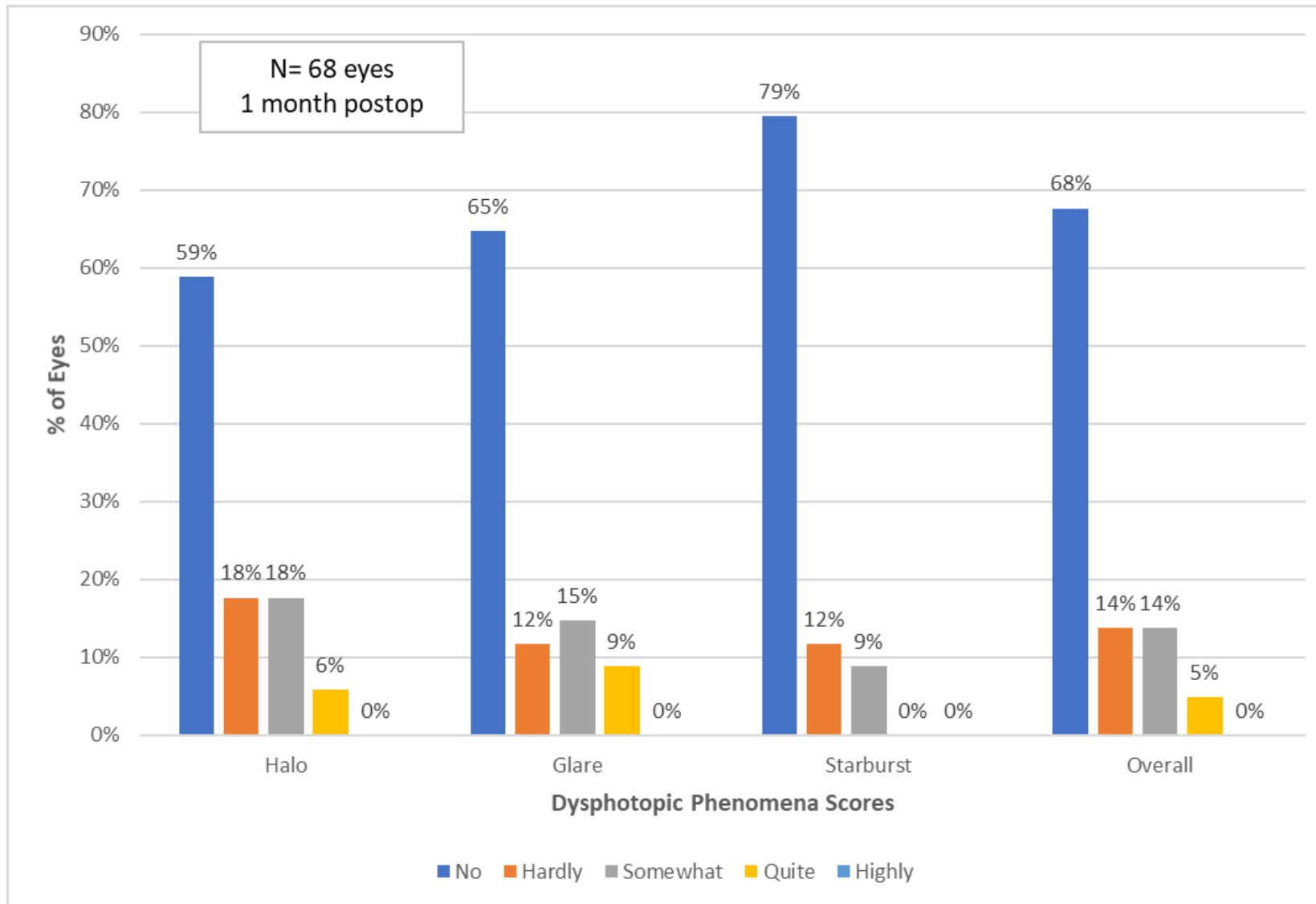
Spectacle Independence



Do you wear glasses?



Dysphotopic phenomena



Do you find following phenomena disturbing? (Likert Scale Score 0 bis 4)

nordBLICK Study results – Poster presentation ESCRS 2019

Title: Sulcoflex Trifocal supplementary IOL for presbyopia correction in pseudophakic eyes

Objective: To evaluate the visual quality after bilateral implantation of a new additive trifocal sulcus IOL in pseudophakic patients.

Setting: nordBLICK Augenklinik Bellevue, Kiel, Germany

Methods: The prospective study includes the first results after bilateral implantation of the new Sulcoflex Trifocal in 10 pseudophakic eyes of 5 patients. All follow-up examinations were performed up to one month after surgery. Subjective refraction, uncorrected and corrected distance visual acuity, intermediate and near visual acuity were assessed.

Result: The patients achieved postoperatively a spherical equivalent of -0.30 ± 0.21 Dpt. The mean UCDVA is binocular 1.08 ± 0.13 (Decimal). The mean UCNVA is binocular 0.8 ± 0.0 and UCINVA 0.92 ± 0.1 . With correction binocular CDVA was 1.2 ± 0.13 , DCIVA 0.96 ± 0.08 and DCNVA 0.84 ± 0.08 . The defocus curve shows good and stable results for uncorrected near and intermediate visual acuity. All patients achieved almost spectacle independence in all visual ranges with very high patient satisfaction. No intra- or postoperative complications occurred.

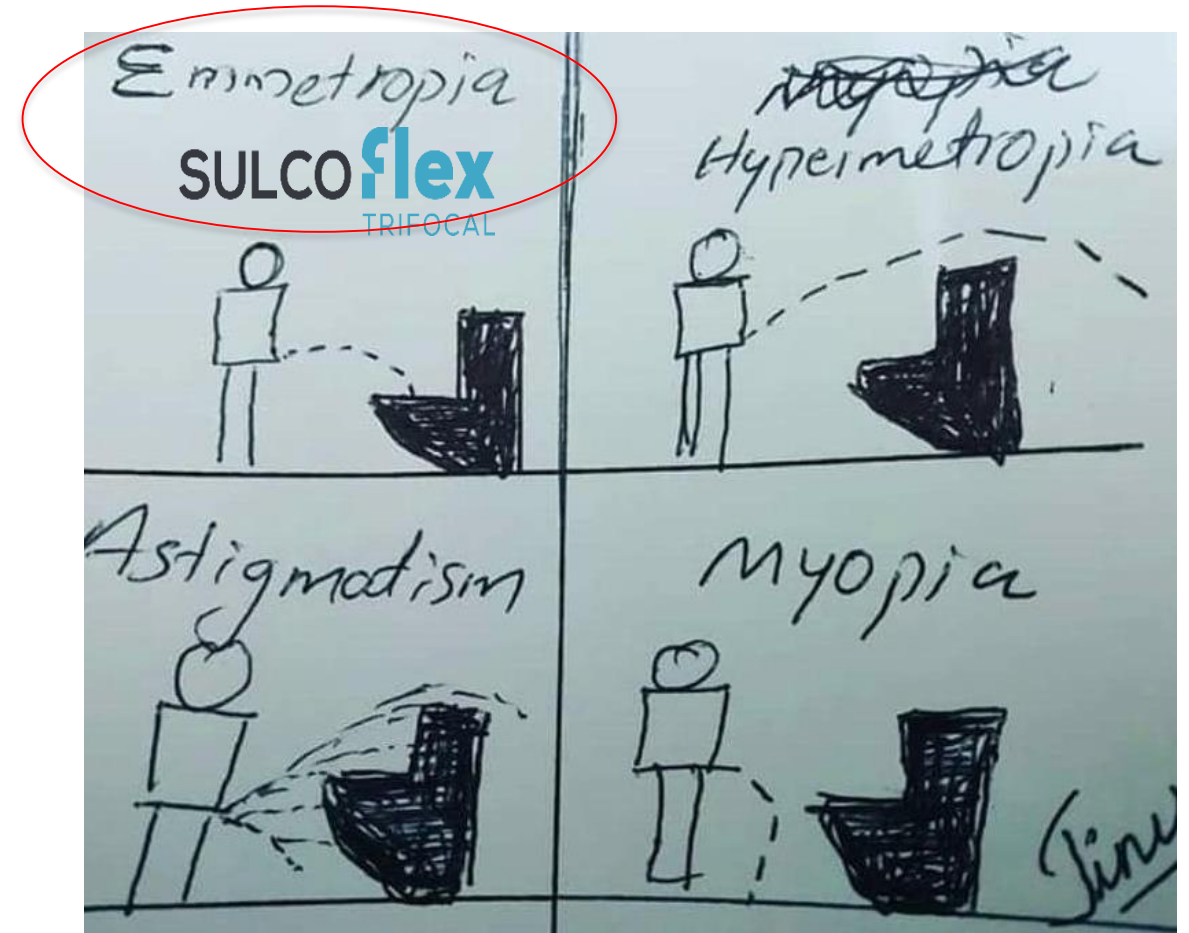
Conclusion: The good functional results one month postoperatively show that Sulcoflex Trifocal is a good option to treat pseudophakic patients with a trifocal optic to improve spectacle independence. Long-term investigations have to follow. As the first additive trifocal IOL, Sulcoflex Trifocal is also a flexible, reversible alternative to trifocal intracapsular trifocal lenses.





Take home message

- Take Home message:
- Sulcoflex Trifocal shows very good results.
- High level of patient satisfaction
- Option for primary or secondary implantation
- New indications like moderate AMD possible!



Thank you.... and Rayner...

nordBLICK



SEHEN. KÖNNEN.

Vielen Dank für Ihre Aufmerksamkeit.