



Proceedings of
A Standardized Platform
and Customized Optics
Hong Kong Seminar 2008

EDITORS

Mr. Charles Claoué

Professor Dr. med. Gerd Auffarth



Mediconcept

Proceedings of
A Standardized Platform
and Customized Optics
Hong Kong Seminar 2008

EDITORS

Mr. Charles Claoué

Professor Dr. med. Gerd Auffarth



Mediconcept

Mediconcept Inc.

Library and Archives Canada Cataloguing in Publication

Standardised Platform and Customised Optics (2008 : Hong Kong, China)
Proceedings of a Standardised Platform and Customised Optics : Hong Kong
seminar, 2008 / Charles Claoué, Gerd Auffarth, editors.

ISBN 978-1-896825-28-1

1. Intraocular lenses--Congresses.
I. Auffarth, Gerd, 1964- II. Claoué, Charles, consultant ophthalmic
Surgeon III. Title. IV. Title: Standardised Platform and Customised Optics.

RE988.S734 2009

617.7'524

C2009-900116-0

This symposium and proceedings publication has been made possible by a continuing medical education grant from Rayner Intraocular Lens Co.

Application and Usage

The authors and publishers have extended every effort to ensure that the application and use of all medical drugs and devices mentioned in this publication are in accord with current recommendations and practices. However, in view of ongoing research, changes in regulations, and the constant flow of information relating to ophthalmology, the reader is cautioned to consult the package insert of any product for changes, warnings or precautions prior to usage. This is particularly important when the product is either new or infrequently used.

All rights reserved

No part of this publication may be translated into any other language, reproduced, or utilized in any form or by any means, electronic or mechanical, including photocopying, recording, microcopying, or by any information storage and retrieval system without prior written permission from the publisher.

Prepared, printed and published in Canada by:

Mediconcept Inc.
3535 St. Charles Blvd.
Suite 201
Montreal, Quebec, Canada H9H 5B9
Tel.: (514) 426-5150
Fax: (514) 426-3442

Copyright 2009 Mediconcept Inc.

Contributors



Mr. Charles Claoué, MA, MD, DO, FRCS, is a corneal fellowship trained Consultant Ophthalmic Surgeon specializing in advanced cataract and comprehensive anterior segment surgery, including refractive surgery. He is senior consultant at the Queen's Hospital, London, and in independent private practice. Mr. Claoué was trained at the

University of Cambridge and at St. Thomas' Hospital, London and Moorfields Eye Hospital. He has a long-term interest in presbyopia surgery and advanced intraocular lens design. He is an honorary clinical lecturer to the University of London, Queen Mary College, and honorary consultant ophthalmic surgeon to the department of ophthalmology at the Academic University of Pretoria, Republic of South Africa. A member guardant of the Worshipful Society of Apothecaries of London, Mr. Claoué is also a Member of the Academy of Experts. He has published approximately 80 peer-reviewed articles.



Dr. Brian Harrisberg, MB, BCh, FRACS FRANZCO, Ophthalmic Surgeon, is in private practice in Newtown, NSW, Australia and sub-specializes in cataract and refractive surgery.

Dr. Harrisberg has published research papers in peer-reviewed journals and has presented lectures in Australia and at international ophthalmology meetings and conferences. He is a clinical lecturer at Sydney University and is Visiting Medical Officer and current Head of Department of Ophthalmology at Royal Prince Alfred Hospital.

Dr. Harrisberg is a fellow of the Australia & New Zealand College of Ophthalmologists, a member of the Australian Society of Cataract & Refractive Surgeons, and a member of the American Society of Cataract & Refractive Surgery.



Dr. Guenal Kahraman, MD, obtained his medical degree at the Ege University, Izmir, Turkey, and his PhD in Hospital Management at Vienna University of Economics and Business Administration. He is currently in residency at the Department of Ophthalmology and Optometry of the Medical University of Vienna.

Since 2000, Dr. Kahraman has worked with Dr. Michael Amon, developer of the Sulcoflex™ intraocular lens. His research interests include cataract surgery, biocompatibility of intraocular lenses, and inflammatory diseases of the eye.



Dr. Margaret Kearns, MBBS (Sydney), FRANZCO FRACS, practices in Sydney, NSW, Australia. She is a Director of The Sydney Eye Specialist Centre along with her husband Dr. Richard Smith. The centre is privately owned and operated by them, with operating suites for cataract and refractive surgery and extensive consulting facilities

for comprehensive eye care.

Dr. Kearns is a Visiting Ophthalmologist at Royal Prince Alfred Hospital. She has a special interest in refractive surgery, including measuring visual outcomes and patient satisfaction, and presented papers on these topics at the winter meetings of the ESCRS Barcelona 2008 and AUSCRS 2008. She has a very long-term interest in diabetic eye disease and its treatment.

Contributors



Dr. Keiki R. Mehta, MBBS, DOMS, MS (Ophth), DO (Ireland), DO (London), FIOS (USA), is Medical Director and Chief of The Mehta International Eye Institute and Colaba Eye Hospital, Colaba, Mumbai, specializing in intraocular implants, glaucoma, phacoemulsification, and refractive laser surgery.

Dr. Mehta has won numerous awards in India and internationally, including the Triple Ribbon Award of the American Society for Cataract & Refractive Surgery for Outstanding Research presentations in ophthalmology in 1998. He has conducted live surgical workshops in every major city in India, and has trained thousands of doctors in intraocular implant surgery and phacoemulsification.

In 2008, he was awarded the Padma Shri Award by the Government of India for his outstanding contribution to ophthalmology.



Dr. Zhenping Zhang, MD, PhD, is a professor and deputy chair of the Department of Cataract Surgery Center, Zhongshan Ophthalmic Center, Sun Yat-sen University, Guangzhou, China. Dr. Zhang has practiced cataract and refractive surgeries for over 20 years. He has performed over 50,000 cataract surgeries, and has published 90 articles on

cataract surgeries and ophthalmic research. He is a member of AAO and ASCRS. Dr. Zhang has written two books, and has contributed five chapters in other publications. His first book, *Lens Disorders and their Surgical Management* was published by Guangdong Technological Publishing House in 2005. His second book, *Intraocular Lenses in the Refractive Surgery Era*, will be published by People's Health Publishing House in Beijing in July 2009.

Contents

The C-Flex Experience	7
<i>Zhen-Ping Zhang, MD, PhD</i>	
The Use of M-flex™ in Pediatric Cases	9
<i>Keiki Mehta, MBBS, DO</i>	
Comparison of Toric IOLs	13
<i>Margaret Kearns, MBBS, DO</i>	
A Platform for Customized Piggy-back IOL Optics	15
<i>Gunul Kahraman, MD</i>	
Pearls for Successful Implantation of The Rayner T-flex™ Toric IOL	17
<i>Brian Harrisberg, MB</i>	
IOL Design for the 21st Century: The IOL Platform	21
<i>Charles Claoué, MA, MD</i>	

The C-flex Experience

Dr. Zhen-ping Zhang

Professor of Ophthalmology

Zhongshan Ophthalmic Center

Zhongshan University

Guangzhou, China

Dr. Zhang introduced his topic by stating that in 1995, he used a three-piece AcrySof®. Since 1999, 100% of patients have been implanted with foldable intraocular lenses, including hydrophobic, hydrophilic and silicone lenses. However, he recounted that he sought out Dr. David Apple in 2001 because of a hydrophilic scare. Some lens discolouring and opacification occurred three to six months following surgery and some of the lenses were even explanted from patients' eyes. Dr. Apple told him that the problem did not stem from the doctor but rather, the material. Dr. Apple also disclosed a secret: the best hydrophilic lens is Rayner.

The objective of Dr. Zhang's study was to evaluate the performance and stability of the C-flex® 570-C intraocular lens with slit-lamp OCT, which recently became available in Dr. Zhang's center (Fig. 1).

The first issue he raised was centration stability. Cross-sectional images were recorded using slit-lamp OCT, one week and one month post-surgery, as depicted in Fig. 2.

Tilt and decentration were measured at vertical and horizontal meridians with MB-ruler software. The results from 37 eyes showed decentration of 0.19 mm around the x axis and 0.18 mm around the y axis. The tilt was approximately 1° around both the x and y axes, which is quite minimal and may be clinically insignificant. As a result, Dr. Zhang recommends Rayner C-flex as the optimal platform for multifocal intraocular lens.

The second element Dr. Zhang pointed out was axis and refraction stability. Anterior chamber depth (ACD) was better with the slit-lamp OCT for evaluation of stability along the optic axis of Rayner intraocular lens, one day, one week, and one month after surgery.

Also, refractive status was examined for evaluation of refractive shift one day, one week and one month after surgery. There was no significant axial shift one day, one week and one month post-op. Without ACD, values and refractive states were extremely stable.

The third element Dr. Zhang mentioned was rotational stability. Limbus registration was done with a

slit-lamp camera before surgery. Digital photographs were taken immediately after surgery under a microscope and photos of retro-illumination were taken by slit-camera one week and one month after surgery. Fig. 3 presents the results from 30 eyes. The degree of rotation is roughly 1.45 and 1.7 (Fig. 4).

The fourth element Dr. Zhang discussed was PCO. He compared the Rayner 570-C and 570-H intraocular lenses in patients, using E-PCO-2000 software to evaluate PCO score. Fig. 5 shows magnified photos of the Rayner 570-H six months after surgery. Dr. Zhang noted that there is some cyl indicated. Both sets of PCO scores were extremely low: roughly 0.021 in the 570-C group, with

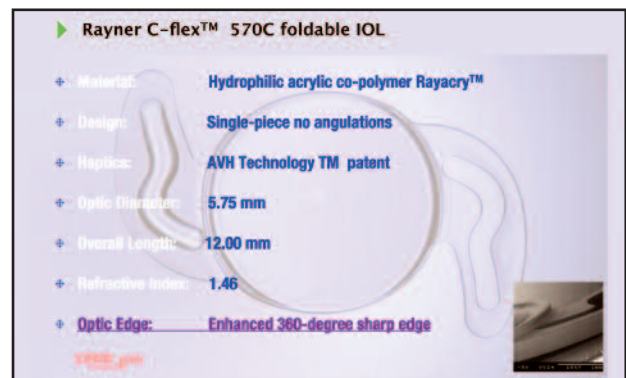


Fig. 1 Study on Rayner C-flex 570C foldable IOL.

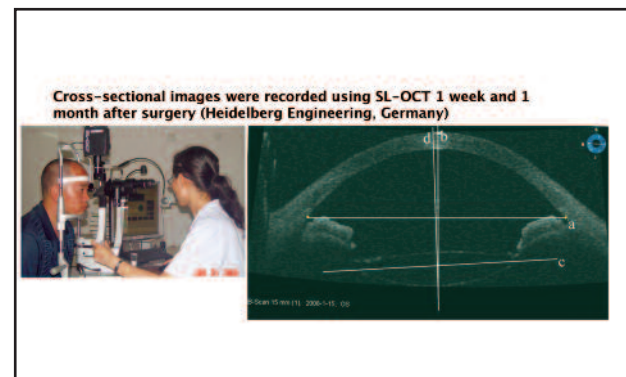

Fig. 2 Examining centration stability.

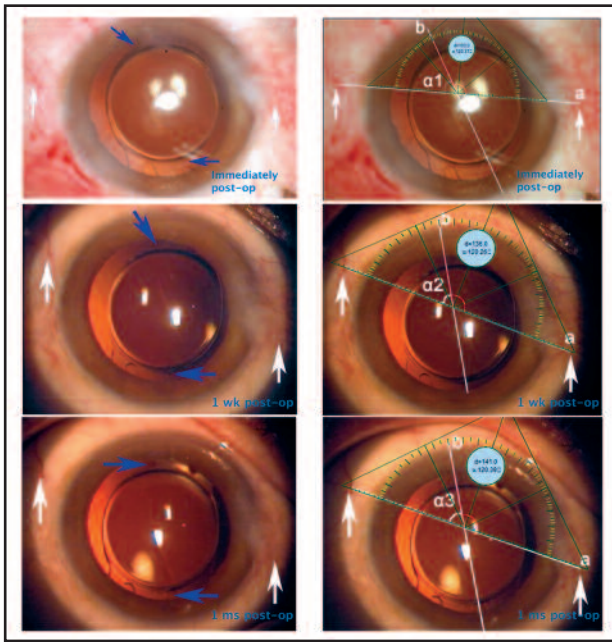


Fig. 3 Rotation: 1 week and 1 month post-op.

► Eyes: 30 (27 patients aged 68.31 ± 6.33 yrs)

► Degree of rotation was almost not found

IOL rotation: $0.45^\circ \pm 0.24$ of $\alpha_1 - \alpha_2$ ($0.12 \sim 0.93^\circ$)
 $0.47^\circ \pm 0.28$ of $\alpha_1 - \alpha_3$ ($0 \sim 0.98^\circ$)

Fig. 4 Minimal rotation demonstrated.

► PCO score was 0.021 ± 0.015 in 570C group and 0.025 ± 0.020 in 570H group 3 months after surgery ($P < 0.05$).

► PCO score was 0.053 ± 0.180 in 570C group and 0.122 ± 0.218 in 570H group 6 months after surgery ($P > 0.05$).

Fig. 5 Low PCO score.

the number in the H group six months post-op showing very little significant difference.

PCO formation in the *C-flex* intraocular lens post-surgery seemed significantly lower than that of earlier models. Dr. Zhang's conclusion is that the *C-flex* 570-C intraocular lens with the enhanced edge seemed to improve PCO prevention clinically. Dr. Zhang highlighted that these features can potentially facilitate earlier spectacle prescription and quicker visual rehabilitation for patients after surgery.

Dr. Zhang concluded by saying that in light of the results he has seen, he maintains that the Rayner *C-flex* is an optimal platform for refractive surgeries.

Dr. Claué noted that in intraocular lens circles, there is always the discussion as to whether one should compare lens PCO by photographic mechanisms, which are highly scientific, or by YAG capsulotomy rates, which are highly clinical. His conclusion is that there is no one right method for doing this, but rather, that they both allow a valid means of comparing two lenses.

The Use of M-flex in Pediatric Cases

Prof. Dr. Keiki R. Mehta

Professor of Ophthalmology, D. Y. Medical College
Medical Director, Chief of the Mehta International Eye Institute
Mumbai, India

Dr. Mehta began his presentation by stating that pediatric cataract surgery is a challenging surgery that has changed significantly in the past 20 years. He stated that the key reasons why it has succeeded to such a great extent are, essentially, the better instruments available, the earlier surgery now being performed, and the availability of high-quality, multifocal implants.

Dr. Mehta emphasized the importance of remembering a few fundamental facts: the critical period of visual maturation occurs at the three- to four-month period. Furthermore, an interesting fact was highlighted by Dr. Jules Stein, that the ability to see near and at distance is important for children in order for them to be able to develop depth perception (stereopsis) and enhanced visual development.

For a number of years, prior to commencing multifocal intraocular implants which he had done approximately nine years earlier, Dr. Mehta and his colleagues were giving varifocal lenses to all children. As he pointed out, it is sad to see a child trying to squint through a pair of bifocal glasses. To his surprise, they found that children adapted to varifocality extremely rapidly; there was never a complaint. As a result, they thought it was an excellent idea and that they should try, in the cases where they were naturally indicated, to start utilizing multifocal lenses. The surgical plan is the same as always in a bilateral complete, or a unilateral complete cataract. Dr. Mehta suggested that the procedure be performed as soon as possible, particularly if the visual axis is compromised by a cataract. In children, Dr. Mehta prefers to use general anaesthesia with positive pressure insufflation, which results in a very soft eye, with a deep anterior chamber. He uses a high viscous viscoelastic, essentially, VisCoat® to do the primary rhexis, although he prefers Healon® at the time of lens implantation.

ADVANTAGES OF THE M-FLEX®

Dr. Mehta stated that he has used a number of lenses over the years, predominantly ReZoom® and ReStor®. The CareGroup out of India made a lens called Prezoil which

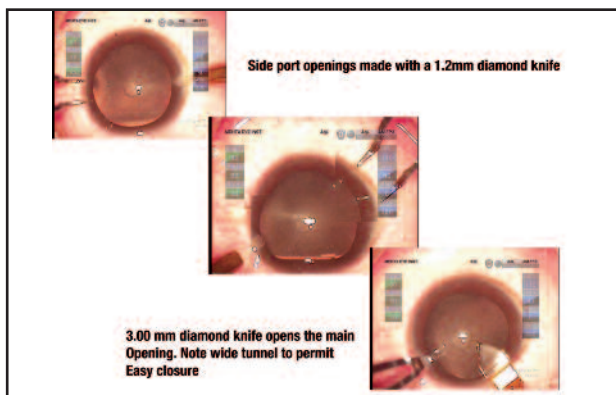
was a cost-effective option for disadvantaged patients. However, over the past few months, or in just a little less than a year, his team has switched over to the Rayner multifocal lens, which offers several advantages, the key one being that it has an aspherical, aberration-neutral refractive optical surface and an enhanced square edge. In children, capsules thicken very quickly and will need to have YAG at an earlier age. Interestingly, one can observe a certain degree of pseudo-accommodation, which is at the intermediate zone, rather than only at distance and near.

The question often asked is, “If you were happy with those (ReZoom and ReStor), why did you change?” The reason is that the best diffractive IOLs are only about 80-82% efficient, as diffractive optics are associated with an 18-20% contrast loss to higher order aberrations. This can be attributable to reflections and light scatter from the facet returns of the diffractive zonal interfaces. The M-flex® does not have this problem and Dr. Mehta stated that he has not had any complaints of unwanted photopic phenomena.

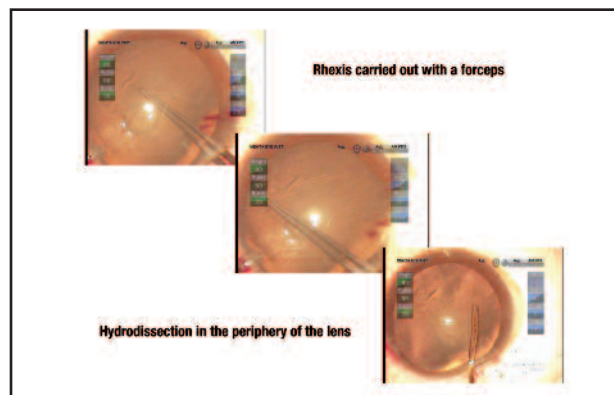
Physical ocular characteristics are obvious, stated Dr. Mehta. Fig. 1 shows the IOL power of the dioptic carriers. Those are naturally not the powers available to practitioners. What tends to happen is that the axial length

IOL POWER:	
Children below 2 years	
1. Do biometry and <u>undercorrect</u> by 20%	
2. Use only axial length:	
17 m.m.	28 D
18 m.m.	27 D
19 m.m.	26 D
20 m.m.	24 D
21 m.m.	22 D

Fig. 1 IOL power of dioptic carriers.



Figs. 2 Preparation for implantation procedure.



Figs. 3 Preparation for implantation procedure.

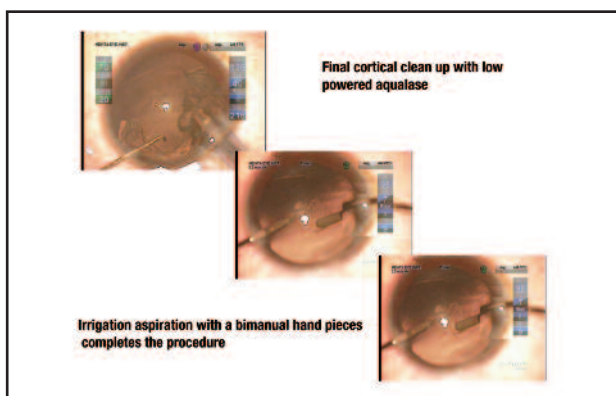


Fig. 4 Final clean-up with Aqualase.

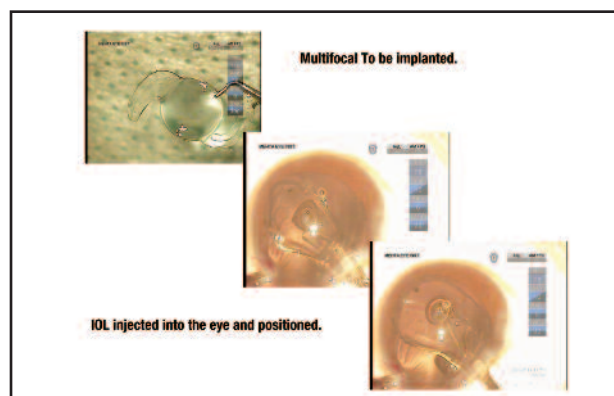


Fig. 5 Multifocal IOL implantation.

is used to roughly evaluate what *should* be the required power of the patient, but practitioners tend to under-correct by 10%.

In children, capsules thicken very quickly and will need to have YAG at an earlier age, which is why Dr. Mehta prefers to do a posterior rhexis, conducted during surgery, which in his opinion is mandatory in all children below the age of 12.

Dr. Mehta does not feel that it significantly cuts down the thickening of the posterior capsule if no blood remains in the eye following surgery in the post 12 years.

Dr. Mehta uses the Alcon Aqualase® technique which, surprisingly in his opinion, Alcon has discontinued. It uses warm fluid pulses, rather than a high-frequency mechanism. Its greatest feature is that it has a polymer tip at the end, which minimizes the risk of posterior capsule rupture, including the convex posterior capsule of children. The other tremendous advantage is that it tends to polish the posterior capsule. Dr. Mehta pointed out that he presented a paper at the ASCRS in 2007 which shows that this polishing of the posterior capsule with the pulsed warm water of Aqualase leaves shiny capsules that do not

opacify early. He feels that this technique does represent a significant difference.

Dr. Mehta described his procedural technique: he performs the rhexis and uses the hot pulsed BSS from the Aqualase at 65° C, which provides an extremely smooth and safe action. As shown in Figs. 2 and 3, he makes standard side port openings with a diamond knife, and uses a rhexis forceps to swing the rhexis around. Subsequently, after a little hydrodissection in the periphery, he simply moves the Aqualase over the surface. He places the tip of the AquaLase in one corner, turns it on, and the lens literally removes itself with no risk of capsule rupture, even if the chamber shallows. The cortical clean-up is first done with the Aqualase (Fig. 4) and capsular polishing is recommended, particularly if there are any residual particles, but more often than not, polishing is not required. Dr. Mehta is very happy with the M-flex multifocal IOL which behaves very well, whereas some of the other lenses have a tendency to vault anteriorly with positive vitreous pressure tending to develop a pupillary capture.

SPECIAL CONSIDERATIONS IN CHILDREN

Naturally, with the Aqualase, the ultrasound part is zero. Dr. Mehta has been utilizing the *M-flex* for children, and begins implanting at a very early age. He stated that he has been doing implants in children from 1976 but for the past nine years, he has been implanting multifocals; in fact, his personal view is that all children should have multifocals because they work extremely well. In his experience, no child has ever complained of flare, glare, double vision, or any other problem.

There are the odd few complications, such as chamber shallowing for the first three days, slight iritis, and an occasional rise in IOP, but this is basically because sometimes a little viscoelastic is left inside.

Below the age of two, Dr. Mehta has an interesting technique. He implants the multifocal IOL to match what would be appropriate for the child when he or she grows up, and covers the residual power with a removable piggy-back HEMA IOL, which is a domed IOL, as described in a paper that he presented at the American Academy of Ophthalmology three years ago. It is subsequently removed when the child reaches within 3 diopters of the approximate power. One does have to be somewhat careful in one's surgical considerations. The problems in pediatrics naturally occur because one is handling a smaller eye, and there is a tendency for capsular opacification. However, in a fair percentage of cases, the children seem to do very well.

Vision in little babies needs to be tested by rolling a graded sized black marble against a black background from various distances and seeing if the child follows it, or by whether or not they can place one object into another progressively smaller-sized object. Slightly older children can be asked to read.

Dr. Mehta noted that some of the problems of suppression stem from the fact that the children are brought in a little too late and their parents are skeptical. Furthermore, there are really too many opinions. If they go to the next doctor who says, "Multifocals in a baby — never do it!" the trouble starts all over again.

Dr. Mehta stated that he does feel that the Aqualase by Alcon is a good system, especially for those practitioners who tend to do implants in a large number of children.

He also stated that he is very happy with the *M-flex* for another reason, namely that the lens doesn't tend to vault anteriorly. With the IOL in the capsular bag, pressure can be exerted anteriorly by the vitreous face, particularly as the eye attempts accommodation and the ciliary muscle contracts. However, as the IOL doesn't vault, the posterior chamber is always well maintained, which is essential in a child. While Dr. Mehta does tend to be a little more careful with children, if a positive insufflation system is used, it is possible to manage comparatively well.

IMPLANTATION TECHNIQUE WITH AQUALASE

The Aqualase requires very little on the part of the practitioner, particularly in pediatric surgery. Some ophthalmologists have commented that they can perform the procedure equally well by using what can be termed a "deplugged phaco." In other words, no direct suction is applied and the emulsified lens is expressed via the pressure of the irrigating fluid. In the case of any adherent capsular remnants, they can be removed and the capsule polished at a later stage in the procedure. Dr. Mehta emphasized that it is essential to leave the posterior capsule scrupulously clean. At the critical point of lens insertion, as the leading haptic and optic unfurl, the quality of the Rayner lens can clearly be appreciated as it just "slips into place" (Fig. 5).

At the conclusion of Dr. Mehta's presentation, Dr. Claoué stated that he entirely agreed with him in that it is essential to closely monitor children for emmetropia as quickly as possible. At a later stage they could have LASIK, rather than leaving them with a high hypermetropia leading to suppression. He pointed out to those who have not yet used the *M-flex* that it looks exactly like the *C-flex*® as it is based on the same IOL platform. Therefore, if the ophthalmologist has implanted *C-flex*, it is easy to implant *M-flex*.

Comparison of Toric IOLs

Dr. Margaret Kearns

Director, Sydney Eye Specialist Centre
Visiting Ophthalmologist, Royal Prince Alfred Hospital
Sydney, Australia

Dr. Kearns began her presentation by saying that in June 2006, she was very interested to see the advent of toric intraocular lenses. At that time a colleague, who wanted to be spectacle free, approached her for a consultation. He was 59, hypermetropic, with 2.5 diopters of cyl and a thin cornea. In fact, his was the first case in which Dr. Kearns used the Rayner Toric lens. It proved to be a great success for him, as well as for Dr. Kearns. Subsequently, Dr. Kearns has looked very closely at toric IOLs and has used them to a great extent in her practice.

Dr. Kearns and her colleague, Dr. Richard Smith, have accumulated data on 212 consecutive Toric IOLs. They have used the toric IOL if astigmatism is greater than 0.7 diopters as measured by the Orbscan. Specifically, they have been using the Alcon and Rayner Toric lenses; Drs. Kearns and Smith assessed the refractive outcomes of these at one month.

Over the past two years, the Alcon lenses have been used mainly for the correction of lower levels of astigmatism, while the Rayner lenses, until recently, have been used for correcting higher levels of astigmatism.

Fig. 1 shows the Alcon lenses and the Rayner lenses combined. The orange line illustrates the corneal astigmatism as measured on the Orbscan. With the Alcon lenses, the corneal astigmatism corrected was in the low range between starting from 0.77 D, whereas the Rayner lenses were used to correct in the range of 2 D up to 14 D. Dr. Kearns pointed out that it was very interesting to note that the postoperative astigmatism in all of these cases was much better, on the whole, than preoperatively. The combined results of Alcon and Rayner lenses showed that 88% of the cases had 0.5 diopters of astigmatism or less; 131 with no cyl; 13 with 0.25; 42 with 0.5; 8 with 0.75; 13 with 1.0; and 6 with 1.50 (Fig 2).

In Fig. 3, the Rayner final refractive cylinder shows a little more scatter, because these cases start off with a much higher cyl. They are more difficult to measure accurately on the Orbscan and IOL Master. In addition, some of the astigmatism is not quite regular, and some of the corneas are difficult. However, even so, the result was very satisfactory.

Dr. Kearns stated that she agreed with Dr. Zhang that the toric IOLs are very stable. There were three re-positionings in the group, not because the lenses had moved but rather, most likely because in the early cases Dr. Kearns was in the process of learning to mark the cornea properly: these re-positionings were the result of operator error. There have also been four enhancements for low residual errors, among both the Alcon and the Rayner lenses, which simply reflect a limitation of the technology.

Dr. Kearns emphasized the importance of marking the cornea properly before — and accurately — prior to surgery. She has developed the technique whereby preoperatively, the patient sits at a slit lamp. The slit lamp can move — with slits at 10, 20, 30, and other degrees; the slit lamp beam is lined up with the cornea and marked with a 30 gauge needle. It just pricks the epithelium to show where the angle of the slit lamp is. Of course, as Dr. Kearns pointed out, this is not always possible if there isn't a slit lamp in the pre-op room, but the importance of developing a technique that is accurate for the individual practitioner is very significant.

Dr. Kearns's study conclusion is that the performance of toric intraocular lenses is excellent. Very few refractive adjustments are needed and there are no major risks. She feels that the Orbscan and IOL Master are accurate indicators of corneal astigmatism, on the whole. Finally, she noted, axis placement is crucial.

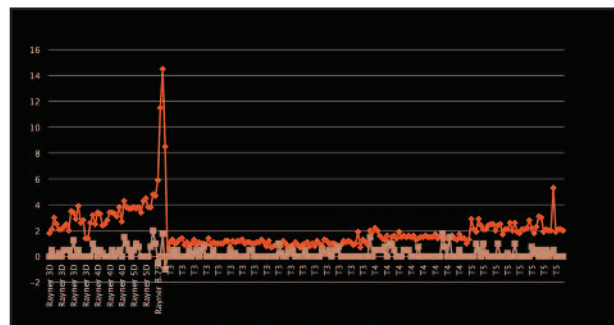


Fig. 1 Combined Rayner and Alcon toric IOL results.

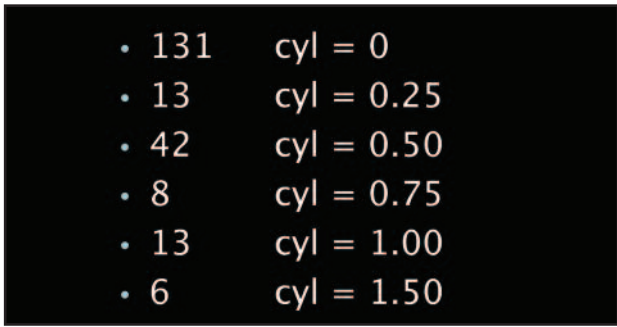


Fig. 2 88% of cases had 0.5 diopters of astigmatism or less.

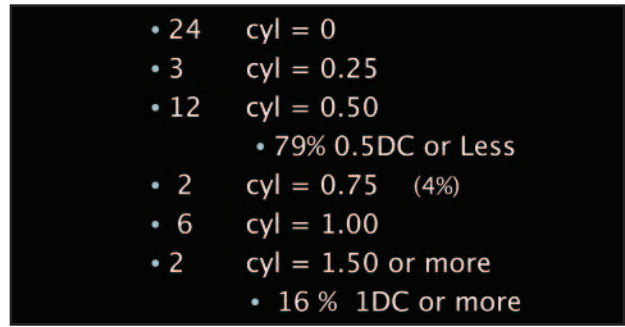


Fig. 3 Rayner: final refractive cyl shows excellent results.

Dr. Kearns uses toric lenses in 50% of cases, and stated that patient satisfaction has been extremely high in her experience.

Dr. Kearns then entertained questions from the audience:

Dr. Claoué: Do you make any adjustment for the effect of the incision?

Dr. Kearns: No, I don't, because I don't feel it is necessary. I don't make the incision on the steep axis; taking the incision into account doesn't seem to make any difference.

Dr. Auffarth: You stated that you use the Orbscan and the IOL Master for calculating the astigmatism, but the two machines use different refractive indices. Do you compensate for this in the calculation, or is this one of the reasons why you have some slight residual astigmatism?

Dr. Kearns: Those things depend a bit on the case. We've found that the Orbscan is more reliable than the IOL Master readings. We do both, and we often use Pentacam as well. But when you get into difficult corneas, you can find the measurements you get on the IOL Master, Orbscan and Pentacam can be very different. On the whole, we use Orbscan, but it isn't always 100%.

Dr. Auffarth: That's quite interesting because we are doing it the other way around. We trust the IOL Master more, but we do the measurement of the IOL Master before we do anything else to the eye. This is because any kind of interference - eye drops, for instance - can change the IOL Master results dramatically. This can greatly enhance the results of the IOL Master keratometry. In addition, topography is always important to exclude any kind of abnormality of the corneal surface. The IOL Master provides numbers alone and doesn't show the entire map of the cornea. The two together provide the complete picture.

A Platform for Customized Piggy-back IOL Optics

Dr. Guenal Kahraman

Medical University of Vienna
Department of Ophthalmology
Vienna, Austria

Dr. Kahraman began his presentation by pointing out to the audience that patients have high expectations after routine cataract surgery. He stated that, of course, a refractive surprise after cataract surgery is very unpleasant for the ophthalmologist and extremely frustrating for the patient. Despite technological developments and the accuracy of intraocular lens calculations, a pseudophakic refractive error is not a rare event.

Dr. Kahraman then went on to discuss polypseudophakia, the situation when more than one intraocular lens is implanted in the same eye. This can be done primarily, which means that both lenses are implanted during the same session, or it can be done as a secondary procedure to correct pseudophakic ametropia.

In 1993, Guyton et al reported the first implant of two intraocular lenses in a capsular bag to achieve high refractive power, but there were some complications. Interlenticular opacification pearls and pigment cells were observed. Also, if two biconvex IOLs were implanted in the bag, hyperopic shifts through IOL surface deformation at the point of IOL contact might be seen.

Amon and his colleagues designed a new lens as an alternative to laser surgery. *Sulcoflex*[®] is intended for implantation in the ciliary sulcus and is manufactured from a hydrophilic acrylic material noted for its uveal biocompatibility.

The lens optic has a round edge and a concave posterior surface (Fig. 1).

Sulcoflex has a 6.5 mm optic with 13.5 mm haptics and a posterior haptic angulation of 10°. The haptics feature a unique undulating configuration, providing very good centration with rotational stability. Additionally, the soft haptics and round edges reduce tissue reaction.

In Dr. Kahraman's pilot study (Fig. 2), there were ten eyes from six patients. Three eyes had the multifocal version of the *Sulcoflex*; three eyes had multifocal lenses before the *Sulcoflex*, and four eyes had a Nd:YAG capsulotomy before the lens implantation.

The patients' mean age was 56 years and the refractive error was between 2 and +2 diopters. The patients were followed for a period of one year. Using a laser flare cell meter, as well as UBM and Pentacam, photos were made and the investigators measured eye pressure, visual acuity and refraction, the latter of which Dr. Kahraman considers essential. Surgery was done under topical anesthesia and piggy-back IOL implantation was performed using the Rayner injector. No intraoperative complications were observed. The results showed that eye pressure was within normal range, with even less postoperative anterior chamber flare compared with that which occurred following regular phacoemulsification. No iris trauma was observed (Fig. 3).

The results also showed that all the lenses were well centered; no rotation, tilt or pigment dispersion was observed. All IOLs were in the ciliary sulcus and there was always a positive iris distance. None of the patients had optic capture. Uncorrected visual acuity was 0.9 and the refraction range was +/0.25.




Fig. 1 Advantages of *Sulcoflex*.

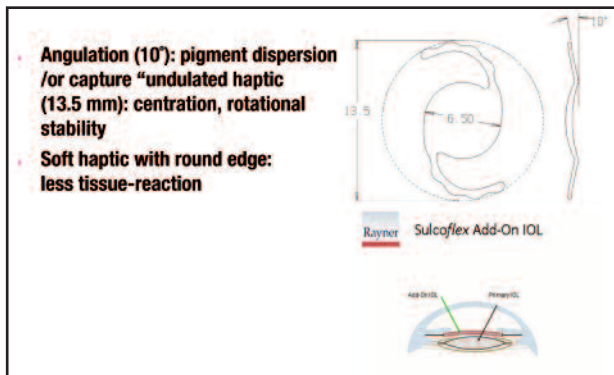


Fig. 2 Sulcoflex pilot study.

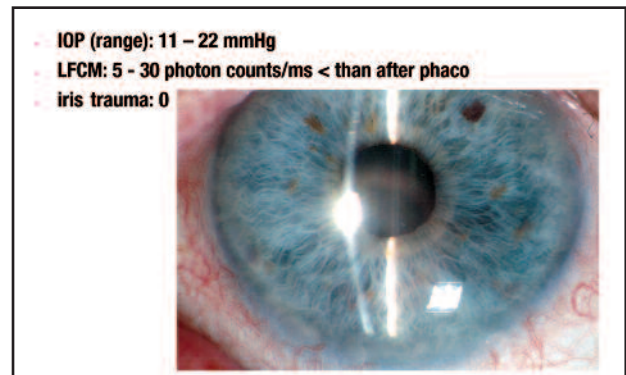


Fig. 3 Pilot study result.

INDICATIONS FOR THE SULCOFLEX LENS

A secondary implantation can be used to correct pseudophakic ametropia. Additionally, with primary high myopic or high hyperopic patients, should the primary lens of choice not offer a suitably low or high power, a Sulcoflex Pseudophakic Supplementary IOL can be implanted as part of the primary procedure.

In addition, as Dr. Kahraman pointed out, there are multifocal and toric versions of Sulcoflex.

Pediatric cataract is a further indication for the ongoing

correction of pediatric pseudophakic changes during the growth and development phases of childhood.

Dr. Kahraman concluded his presentation by stating that his results show that implantation of a secondary piggy-back Sulcoflex in the ciliary sulcus, leaving the original IOL in place, is an effective, safe and easy treatment for pseudophakic refractive errors. The surgery has proven to be associated with less trauma, compared with an IOL exchange. Given all this, he contends that Sulcoflex represents a new and promising IOL concept.

Pearls for Successful Implantation of the Rayner T-flex Toric IOL

Dr. Brian Harrisberg

Professor, Royal Prince Alfred Hospital
NSW, Australia

Dr. Harrisberg introduced his topic by saying that although Harold Ridley realized that spherical correction is needed for best visual outcomes, it has taken so long for the profession to come to the conclusion that, in fact, more than spherical correction is needed. He noted that it is only now that ophthalmologists are in a position to take advantage of cylinder correction; and sphere and cylinder are by far the most important aberrations that lead to good unaided visual outcomes. Dr. Harrisberg feels that the correction of aberrations will continue to advance intraocular lens technology.

ADVANTAGES OF RAYNER TORICS

In the 1990s, Dr. Harrisberg was using the Staar plate haptic IOL for post-keratoplasty patients, or for those people with fairly large amounts of astigmatism. At that time, the rotation and fitting of the IOL in the bag were a problem. In fact, as the anterior chamber was hydrated, one could frequently observe the Staar IOL rotation, just through the vector forces induced by the irrigating fluid. More recently, Dr. Harrisberg has been using the AcrySof® Toric IOL, one of its advantages being that it is a sticky lens. However, it is very slow to unfold, and it is often difficult to know when it has reached its endpoint, with the haptic being fully abutted against the equatorial bag. As a result, the surgeon may have finished the surgery not knowing if the AcrySof IOL has fully opened. Dr. Harrisberg has in the last 18 months been using Rayner Toric IOLs and finds the unfolding characteristics much more acceptable.

THE IMPORTANCE OF CORRECT PRE-OPERATIVE DATA

Surgical incisional keratotomies are performed for corneal-based astigmatism where lens surgery is not involved. Dr. Harrisberg stated that he has done arcuate keratotomies and limbal relaxing incisions with cataract surgery, and these have been only partially successful. Arcuate keratotomies can lead to aberrations; in addition,

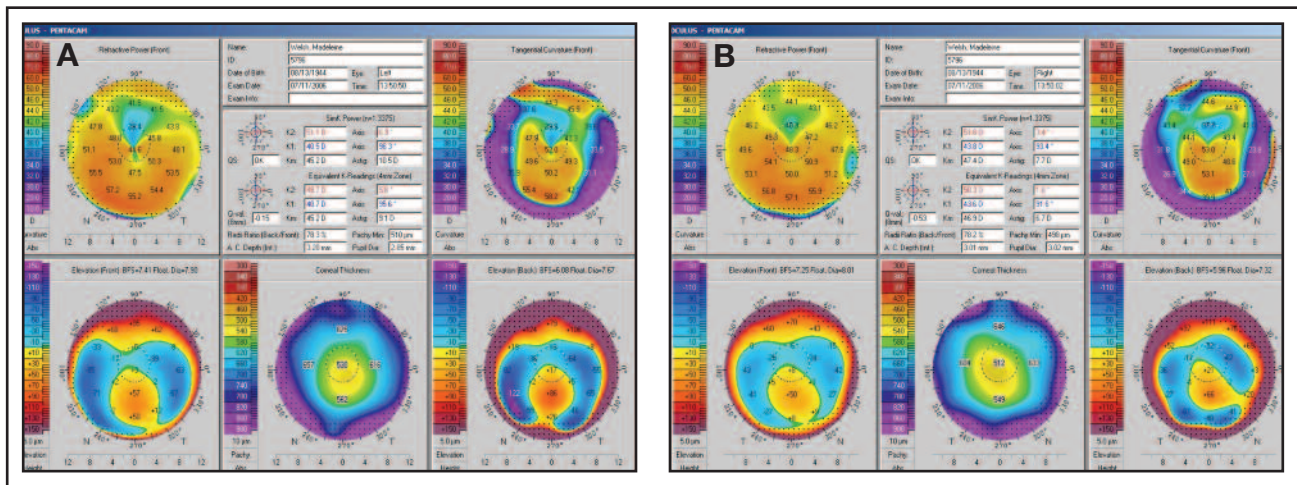
limbal relaxing incisions are not always accurate. Dr. Harrisberg noted that he uses a laser (photo-refractive keratectomy) for corneal-based surgery to correct astigmatism.

The final outcome in cases with toric lenses also depends on accurate preoperative assessment. The surgeon is armed with a complete medical history and determines the patient's needs and expectations prior to surgery. The astigmatic data should be accumulated from many sources, including the spectacle refraction and any form of keratometry. In addition, Dr. Harrisberg feels that corneal mapping is very important.

In terms of the surgery, the only issue being dealt with is corneal astigmatism. As the crystalline lens is being removed, lenticular astigmatism is not a problem. The baseline assumptions in surgery are correct indications and correct refractions. Dr. Harrisberg performs IOL Master readings first, before the corneal epithelium has been touched, allowing better K readings. He performs manual keratometry and corneal mapping, using the Pentacam.

Rayner, in turn, determines the ideal lens power and the surgeon makes a choice, depending on what residual sphere or cylinder is expected, or what would be acceptable. One must always remember that with this type of surgery, the sphere and the toric power must be correct, because if one of these is wrong, the patient will be dissatisfied. When the lens is positioned within the capsular bag, accurate axis positioning is essential.

Dr. Harrisberg cited a study comprising 33 cataractous eyes in patients aged between 56 and 86 years. Four of these 33 eyes had keratoconus, and one had a corneal graft following Zoster keratitis. Approximately 15% of these patients had complex or irregular astigmatism. Dr. Harrisberg mainly inserted toric Rayner IOLs with 2 diopters of cylinder but noted that in this study there is quite a power spread, including higher cylinders. Dr. Harrisberg stated that he had seen some seriously sick corneas, which had been associated with less than perfect results but overall, achieved a high degree of patient



Figs. 1A, B Pentacam maps OS and OD in a patient with keratoconus.

satisfaction. In terms of post-operative target refractions, it should be possible to achieve results within ± 1.0 D but there are some cases — the extreme astigmats — in which patients will still have residual astigmatism.

Dr. Harrisberg contended that visual results will depend on how much residual cylinder is left behind. Patients having a residual astigmatism of between 1 and 2 diopters will usually achieve 6/6 (20/20) or better, while with patients having higher cylinders, 9 to 11 diopters, often have best corrected vision of 6/12 (20/40) or better. This appears highly satisfactory to these patients with complex astigmatism. However, best-corrected visual acuities (BCVA) are increasingly approaching 6/6 (20/20).

Dr. Harrisberg cited a case that occurred about one year previously, of a 64-year-old lady. She had been known to have had keratoconus since the age of 20 years and was wearing contact lenses. She had Map-Dot-Fingerprint corneal dystrophy and recurrent marginal ulcers and in the previous four to five years had become intolerant contact lenses. She was, therefore, spectacle dependent (with a high prescription) and her best-corrected vision was 6/18 (20/16) in both eyes. She was still an independent lady and driving (with difficulty); however, her vision was not within legal driving limits for Australia. She had noticed that she was tripping over objects, at which point Dr. Harrisberg diagnosed cataract with poorly corrected refractive errors.

Fig. 1A illustrates her Pentacam maps, showing the extensive inferior steepening, irregular astigmatism, and anterior and posterior floats: the patient had keratoconus; her central keratometry readings were 40.5 and 51. However, the equivalent keratometry readings, which take into account anterior corneal surface and posterior corneal

surface, are different. Dr. Harrisberg consulted with Dr. Claoué as to how best to proceed.

The other eye (Fig. 1B) shows a huge cone, with keratometry readings of 43.8, 51.6, but the equivalent Ks are smaller. Dr. Harrisberg decided to use the equivalent Ks, aiming to correct the absolute center of the cornea. The surgical team had to choose one point and base their keratometry data on it. Using the equivalent Ks, they designed a custom-made lens, 13 diopters for the sphere, 9 for the cyl, 12.5 diopters for the sphere and 11 for the cyl in the other eye; and chose the axis according to all the data available. The patient's pre-operative BCVA was 6/18 (20/60) best. Her post-operative vision was 6/15 (20/50) and 6/12 (20/40) unaided.

Although she had some residual cylinder, she was satisfied with the result having achieved independent unaided vision and best corrected 6/6 (20/20) vision. An abnormal cornea requires a high cylindrical correction and can achieve very good results, especially with accurate data and confidence in this data.

WOUND CONSTRUCTION

Dr. Harrisberg highlighted the importance of wound construction. He stated that if a lens is going to move at any time, it's going to move in the first one to four hours because that's when the chamber will shallow if there is poor wound construction. What's more, he stated, a lens can tilt, possibly inducing coma, or it may rotate which, in the case of a toric lens, will change the astigmatic correction. In addition, the capsulorrhexis size is important because one wants stability within the capsular bag. Cortical clean up is also essential because one doesn't want anything to displace the lens in any way.

MARKING TECHNIQUES

The pre-operative marking of the cornea is done with the patient sitting and focusing in the distance. Topical anesthetic drops are then administered and Dr. Harrisberg makes one marking pen spot to indicate the six-o'clock and nine o'clock position. Sometimes, these marks may not always be accurately placed, and the surgeon is advised to stand back from the patient to assess the marked axis relative to the vertical meridian.

MAJOR ELEMENTS OF SURGERY

The loading of the lens is done by the technicians. It is important to load the lens in a reverse-S configuration to ensure that it enters the eye for positioning within the capsular bag with the correct orientation. As the injector wings are closed, it is important to check and double-check that the haptics have not been captured within the wings of the cartridge.

The injection process is extremely simple: the lens exits the injector nozzle safely and in a controlled manner, without "shooting," before quickly unfolding within the capsular bag.

There are two diametrically opposed axis markings on the anterior IOL surface which indicate the IOL axis of lowest power. This is intra-operatively aligned with the marked axis of highest corneal power.

Once the lens is well positioned, it is essential to remove all residual viscoelastic from in front, as well as from behind, the lens. Dr. Harrisberg suggests using a tilt

technique in the long axis, to facilitate aspiration from behind the lens, as this technique is less likely to cause rotation.

After once again confirming the correct axis, the process is complete.

The lens is deemed to be sitting perfectly, with good overlap between the capsulorrhexis rim and the optic, and on the aligned axis. Dr. Harrisberg always hydrates the incisional wound and the side port incision - to ensure a seal.

ADVERSE OUTCOMES

If the lens is incorrectly positioned, the outcome will obviously be unsatisfactory. It is also important to note that the higher the power of the lens, the more sensitive the visual outcome will be to axis alignment. Dr. Harrisberg related that as he once observed an entrapped trailing haptic that was captured by the plunger, care must always be exercised in loading. However, as Mr. Claoué pointed out, the injector plunger cannot be expressed through the cartridge and an entrapped haptic will require the lens and injector to be removed as one unit.

In concluding his presentation, Dr. Harrisberg stated that the Rayner T-flex compares favorably with other toric IOLs. It provides a high degree of certainty in maintaining the position of the axis of the lens; the lens sits exceptionally well within the capsular bag, and it delivers safe and accurate outcomes.

IOL Design for the 21st Century: The IOL Platform

Mr. Charles Claoué

Consultant Ophthalmic Surgeon, The Queen's Hospital, London

Honorary Consultant, Dept. of Ophthalmology, Academic University of Pretoria

Honorary Clinical Lecturer, University of London

Consultant to Rayner Intraocular Lenses Ltd.

With reference to the title of this Symposium, "A Standard Lens Platform and Customized Optics," Mr. Claoué stated that he favors it because he believes it's the direction in which intraocular lens design is going to be heading over the next few years.

Mr. Claoué began his presentation by posing the question, "What is an intraocular lens platform?" It is, he stated, everything except the "optics of the optic". This immediately posed a terminological problem, in that the word "optic" refers both to a part of the lens and to its functional performance with light.

He contended, quite clearly, that what is required is a foldable lens. The three materials traditionally used are silicone, hydrophobic and hydrophilic acrylics. While all of these materials have strengths and weaknesses, Mr. Claoué's lecture highlighted the fact that if a given patient requires VR surgery with silicone oil and has a silicone IOL implanted, there will be 100% silicone oil coverage of the lens, which obviously destroys the efficiency of the optic. This is not a problem with hydrophilic acrylics.

THE DIFFERENCES BETWEEN HYDROPHOBIC AND HYDROPHILIC IOLS

Manufacturers of hydrophobic acrylics claim that their lenses are superior. However, independent assessment has demonstrated that they are associated with 35% silicone oil coverage, which is still unsatisfactory. In fact, it's only when hydrophilic acrylics are used that one can achieve an acceptably low silicone oil coverage of less than 5%. However, hydrophilic lenses have two unique advantages. The first is that they are the only materials capable of acting as a drug delivery device, by utilizing a "sponge effect". Mr. Claoué stated his belief that in the very near future — perhaps within the next five years — practitioners will be able to soak lenses in antibiotics, in drugs to inhibit PCO, in anti-inflammatory drugs, and perhaps more.

The second advantage is that hydrophilic acrylics are the only IOL materials existing in two states, the

hydrated state, which is used in surgery, and the dehydrated state which can be lathed during manufacture, using computer-guided, diamond-tipped lathes, into extremely complex optical forms. This cannot be done with compression molded lenses, as they would require a new mold for each optic. As IOL practice moves toward fully customized lenses, this material is going to be the only viable one.

Mr. Claoué noted that several years ago, there were perceived problems with hydrophilic acrylics, several of which had opacified. Some of these lenses were being made from unsuitable materials which had been copolymerized in the form of rods instead of as individual discs. This had posed manufacturing problems, particularly in terms of regulating the temperature of what is a highly exothermic reaction. This resulted in non-uniformity of the porosity of the co-polymer matrix, which contributed to the problem. Another such lens was the HydroView® which as Mr. Claoué remarked, many people in the audience may have actually used. The manufacturers of this lens had encountered an unexpected interaction due to the presence of silicone in the packaging material. However, Mr. Claoué noted that the Rayner hydrophilic acrylic material had existed for ten years and it had never opacified in any normal eye.

Indeed, Mr. Claoué said, all materials can have the propensity to opacify in the eye under certain conditions. Even PMMA, the gold standard, has been known to opacify, as have some hydrophobic acrylics. As a result, one must not think that hydrophilic was historically unique in this respect. Rayner has never had any lens calcify in a normal eye, which they contend is the result of quality control, a statement Mr. Claoué finds credible.

In terms of IOL construction, one-piece lenses are preferable for several reasons. Manufacturers like them because they're cheaper to make but unfortunately, they don't always pass on the low price to ophthalmologists or their patients! However, the ease of injection is so much greater with one-piece lenses compared with three-piece and Mr. Claoué believes that three-piece lenses will become a thing of the past fairly quickly.

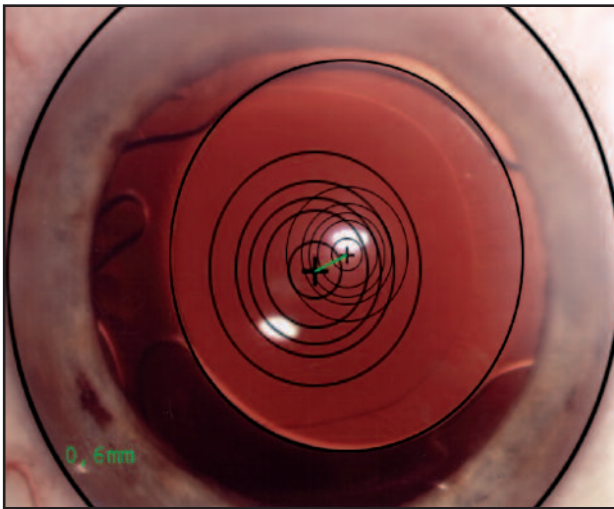


Fig. 1 Table centration.

RAYNER C-FLEX® IOL

As Mr. Claoué travels around the world, he sees an increasing number of copies of the Rayner C-flex lens — clones, one might say — but only one, the Rayner C-flex, is an FDA-approved lens. Indeed, it was the first non-American lens to have been approved by the FDA for over two decades.

The Rayner C-flex lens is provided with a single-use, disposable injector (one free with every lens) and it is possible to achieve an implantation through a 1.8 mm incision using a wound-assisted technique. It has a soft plunger tip that completely occludes the lumen of the nozzle to help prevent IOL capture during injection and a round nozzle profile with a parallel-sided distal tip. This facilitates insertion of the nozzle tip into the eye without stretching the wound, helping contribute to a much safer procedure.

A viscoelastic is sparingly applied to the injector loading bay and nozzle. The lens is then placed centrally within the loading bay, taking care to ensure that it is well tucked under the flanges and the loading bay is closed, ready for injection. Mr. Claoué finds the entire process extremely quick and easy.

THE CRITICAL ROLE OF HAPTICS

Haptics are probably the most “boring” part of the lens and they don’t attract much attention from ophthalmologists. However, they are critical because they are the part of the lens that provides stability. As more complex optics are developed, this stability becomes even more fundamental because without perfect stability, the optics simply will not work. Mr. Claoué pointed out that the

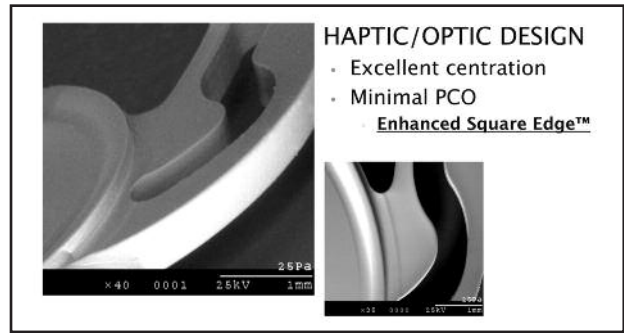


Fig. 2 Minimal PCO due to Enhanced Square Edge.

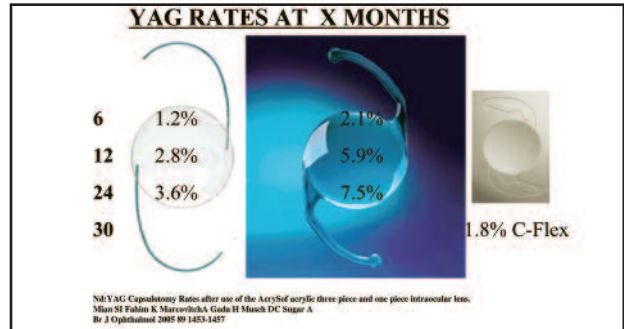


Fig. 3 Lack of square edge doubles YAG capsulotomy rate.

Rayner haptics are of a special closed-loop design incorporating Rayner’s Anti-Vaulting Haptic, or AVH™, Technology (Fig. 1) which helps provide excellent centration with superb stability. Centration and stability is also enhanced by the lens having zero haptic angulation.

Rayner C-flex® IOLs are intended for in-the-bag placement but are also suitable for ciliary sulcus placement in normal eyes. A larger version of the lens, Superflex®, is also available which is especially suitable for the larger myopic eye.

Professor Gerd Auffarth (Heidelberg, Germany) has also clinically evaluated the performance of the unique Rayner haptic design and has concluded that it is a very stable lens. Furthermore, he demonstrated remarkable rotational stability indicating its use as a toric.

In terms of which other features are desirable, one wants absolutely minimal PCO. Mr. Claoué’s studies have shown that at 30 months the Nd:YAG rate is less than 2%. This is because of Rayner’s Enhanced Square Edge™ (Fig. 2) which is characterised by the square edge crossing the haptic-optic interface. If there isn’t a square edge at the interface, then there is an “Achilles heel” in that lens cells can migrate to the visual axis. In fact, the square edge is more important than the material for

PCO prevention; this has been shown in human and animal models.

Fig. 3 shows YAG rates at 6, 12 and 18 months for another three-piece and single-piece lens design. The fact that there is no square edge doubles the YAG capsulotomy rate. So actually, the way the manufacturers make the lenses, in terms of design, does directly impact on patient outcomes.

THE EFFECTS OF IOL COLOR

The majority of studies show no link between blue light and retinal disease; it's UV and violet light that matter. Blue light is needed for good vision and for circadian rhythm to ensure a good sleep cycle and well-being. However, yellow lenses are popular with some ophthalmologists because of their perceived advantage of blue-light blocking. Mr. Claoué expressed his opinion that yellow lenses are a marketing tool that has been used to great effect, but that their popularity has not been based on any evidence. He contended that at this point, in the 21st century, ophthalmologists should be practising evidence-based medicine. One very prominent European

ophthalmologist is explanting yellow lenses from depressed patients, such is the concern about the effect of blue light on circadian rhythms.

Summarizing the features of the Rayner *C-flex*, Mr. Claoué pointed out that it is foldable, injectable and is provided with a single-use injector. It is available in a larger size for myopic eyes, features anti-vaulting haptics for centration and stability and has an enhanced square edge for low PCO. It is manufactured from a hydrophilic acrylic material for biocompatibility and has excellent resistance to silicone oil adherence.

In conclusion, stepping back to look at the larger picture, Mr. Claoué highlighted the impact of IOL implantation by hypothesizing a scenario in which a patient returns to their ophthalmologist and claims, "I can now see!" Naturally, the patient is very happy but that level of happiness may be quite out of proportion with how well they can actually see. Mr. Claoué contended that in operating on people's eyes, ophthalmologists actually operate on much, much more, and give patients a new lease on life; this is, in fact, why patients are usually so happy.

ISBN 978-1-896825-28-1

Mediconcept Inc.