

# Piggybacking With the Sulcoflex

The design of this one-piece lens reduces the risk of interlenticular opacification and iris chafing.

**BY MOHAMMAD I. KHAN, MRCPHTh; AND MOHAMMED MUHTASEB, FRCOPHTH**

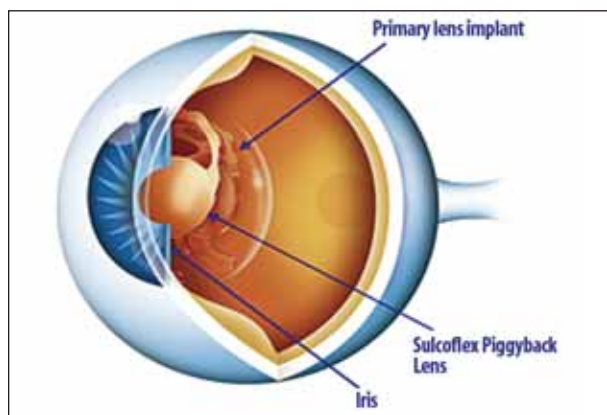
Cataract surgery has evolved from a procedure concerned with safely removing cataracts to a procedure aimed at achieving the best refractive outcome, thanks to advances in IOL technology and phacoemulsification techniques. Although accurate biometry and IOL power calculation are possible, there are occasions when a refractive surprise will still occur postoperatively. Additionally, more patients expect spectacle independence for distance, with increasing numbers of patients requesting spectacle independence for both distance and near vision. Secondary IOL implantation, or IOL piggybacking,<sup>1</sup> can address these issues.

The indications for piggybacking after primary in-the-bag IOL implantation are expanding. They currently include: (1) correction of postoperative ametropia; (2) correction of postoperative astigmatism, including disabling astigmatism after penetrating keratoplasty in pseudophakic patients;<sup>2</sup> and (3) correction of pseudophakic presbyopia.

## BACKGROUND

The piggyback technique involves use of two or more IOLs in the posterior chamber of the same eye. First described by Gayton and Sanders<sup>1</sup> in 1993, this technique was initially developed to correct high hyperopic errors and as a secondary procedure to correct postoperative refractive errors.<sup>1-4</sup> Implanting a second IOL in the posterior chamber is a relatively easy and atraumatic procedure that is not associated with the risk of potential complications seen with IOL exchange. Additionally, the accuracy of IOL power calculation is theoretically higher than in IOL exchange.<sup>2</sup> Piggybacking with PMMA, silicone, or acrylic IOLs has been successful in myopic, hyperopic, and overcorrected pseudophakic patients.<sup>1-8</sup>

The first piggybacked multifocal IOL—the Array (Abbott Medical Optics Inc., Santa Ana, California; no longer available)—was described by Mejía<sup>5</sup> in 1999. Two years later, Donoso and Rodríguez<sup>6</sup> reported on a series of five patients implanted with the Array. They concluded that piggyback IOL implantation with a multifocal lens was a safe, efficient procedure that yielded good



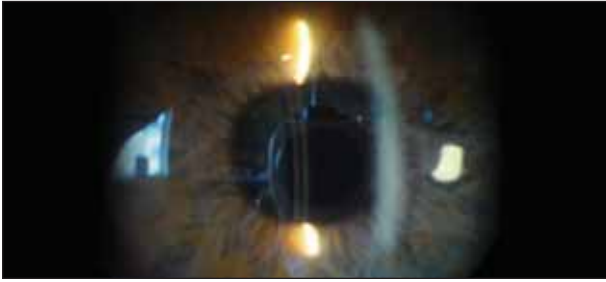
**Figure 1.** The Sulcoflex is separated from the iris anteriorly and the primary IOL posteriorly.

refractive results. Following this study, there have been numerous publications reporting the safety and efficacy of piggybacking IOLs.

One of the most important late complications with piggybacking has been interlenticular opacification (ILO). This complication causes a hyperopic shift and results in opacification in the space between the two IOLs.<sup>9</sup> Initial studies suggested that ILO was particularly seen when both IOLs (especially acrylic lenses) were implanted in the bag through a small capsulorrhexis.<sup>10</sup> Although the exact cause of ILO is unknown, it is postulated that bioadhesion of the anterior lens to the anterior capsule and the posterior lens to the posterior capsule may prevent cell migration from the equatorial bow to the posterior capsule. This migration may be directed toward the interlenticular space, resulting in ILO. With improvements in lens designs, implantation of the piggybacked IOL in the sulcus has resulted in a reduced incidence of ILO.

## THE SULCOFLEX

The Sulcoflex (Rayner Intraocular Lenses, Ltd., East Sussex, United Kingdom) is a one-piece hydrophilic acrylic IOL with a 6.5-mm optic and 13.5-mm overall length. The optic has a round edge with a concave posterior surface



**Figure 2. Case 1:** A quiet eye showing clear implants and a nice gap between the two implants.

and convex anterior surface. The haptics have 10° posterior angulation. These characteristics ensure separation of the IOL from the iris anteriorly, and the primary IOL posteriorly, resulting in significant reduction in the risks of ILO and iris chafing (Figure 1). The Sulcoflex can be used to correct pseudophakic spherical ametropia, pseudophakic astigmatic ametropia, or pseudophakic presbyopia.

The first aspheric Sulcoflex IOL was implanted in May 2007 and the first Sulcoflex multifocal IOL in September of the same year. More than 1,000 Sulcoflex IOLs have been implanted, and, according to the company, there have been no reports of uveitis, iris chafing, glaucoma, explantation, or ILO.

Both the optic and haptics have round edges to reduce trauma to the posterior iris surface. The thickness of the optic varies between 0.25 and 0.75 mm, depending on its dioptric power (Table 1). The thickness of the haptics is 0.33 mm.


## **SURGICAL TECHNIQUE**

The surgical technique is fairly straightforward but warrants a brief description for the beginning surgeon. A 2.6-mm clear corneal incision is made, followed by injection of a cohesive ophthalmic viscosurgical device (OVD) into the anterior chamber and sulcus. Folding of the Sulcoflex IOL is performed under the operating microscope to ensure correct lens positioning. The lens is injected into the sulcus with subsequent careful positioning and centration of the IOL.

In the case of the Sulcoflex multifocal IOL, aspiration of OVD (including from the interface) is followed by

### **TAKE-HOME MESSAGE**

- The Sulcoflex can be used to correct pseudophakic spherical ametropia, pseudophakic astigmatic ametropia, or pseudophakic presbyopia.
- Both the optic and the haptics have round edges to reduce trauma to the posterior iris surface.
- To date, the Sulcoflex IOL has not been reported to cause uveitis, iris chafing, glaucoma, explantation, or ILO.



**Figure 3. Case 2:** Clear implants with a gap in between the IOLs.

injection of acetylcholine chloride to constrict the pupil, allowing the surgeon to confirm that the lens is centered.

Intracameral cefuroxime antibiotic injection completes the procedure. Iridotomy is not required in routine cases but may be considered in certain circumstances, such as in short eyes or when there are unusual features that predispose to angle closure. An iridotomy may be created preoperatively with an Nd:YAG laser or at the time of surgery.

## **CLINICAL CASES**

The following cases involved implantation of the Sulcoflex multifocal or Sulcoflex toric IOL. All four cases demonstrate good outcomes without complications.

**Case 1.** A 56-year-old university professor had a history of myopic astigmatism that was corrected with LASIK in 2000. She developed cataracts, and by 2007 her visual acuity was reduced to logMAR 0.18 in both eyes. The patient had uneventful sequential cataract surgery with implantation of Tetraflex IOLs (Lenstec, Inc., St. Petersburg, Florida) in April and May 2008. Her previous history of LASIK, contraindicated the use of multifocal IOLs. She initially had good vision, with logMAR 0.1 and N5 in the right eye and 0.0 and N10 in the left. Gradually she noticed increasing problems due to reduced near vision. As the patient was keen on spectacle independence, Sulcoflex multifocal IOLs (plano sphere with 3.50 D add) were implanted in both eyes after a complete discussion of the risks involved. The patient was delighted with the results, and, at 12 months follow-up, she maintains UCVA of logMAR 0.0 and N5 in both eyes. This patient is spectacle independent and maintains normal intraocular pressure (IOP) with no signs of ILO or iris chafing (Figure 2).

**Case 2.** A 61-year-old patient had uneventful cataract surgery with monofocal IOL implantation at another center and ended up with a refractive surprise of 3.00 D and UCVA of logMAR 1.0. After a detailed discussion of the options, we planned to implant a Sulcoflex multifocal IOL, but we decided to treat the cataract in the fellow eye first. This patient was pleased with the distance and near UCVA provided by placement of the MFlex multifocal IOL (Rayner Intraocular Lenses Ltd). Subsequently, she underwent piggy-

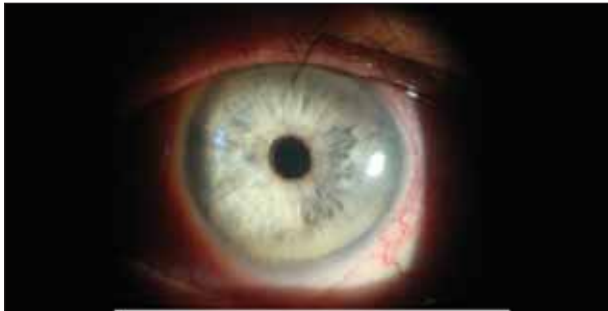

Figure 4. Case 3: A quiet eye with a clear implant.

back implantation of the Sulcoflex multifocal IOL (4.00 D sphere with 3.50 add) in the first eye. Postoperatively, the patient was happy with UCVA of logMAR 0.06 and N6 after implantation of the Sulcoflex multifocal IOL. She had a refraction of 0.00 -0.75 X 120° with normal IOP and no evidence of iris chafing at 6-month follow-up (Figure 3).

**Case 3.** A 58-year-old professional snooker player presented to the emergency room in 2006 with a retinal tear in his right eye. He had a history of bilateral LASIK 13 years prior to presentation. The tear was successfully treated with argon laser, but he presented again 2 years later with a retinal detachment in his left eye. He underwent pars plana vitrectomy with gas, and the retina was successfully reattached. However, he developed cataract. The patient underwent uneventful cataract surgery and implantation of a monofocal AcrySof SA60AT IOL (Alcon Laboratories, Inc., Fort Worth, Texas) in December 2008, with a postoperative refractive surprise of 3.00 D. His UCVA was logMAR 0.78 (0.3 with pinhole) and, as his left eye was the dominant eye, he was unable to play snooker (even with new glasses). After discussing all possible options, he underwent implantation of a Sulcoflex multifocal IOL (4.00 D with 3.50 add) in September 2009. He was delighted with the result, as he had plano refraction and UCVA of logMAR 0.07 and N6 at 6 months postoperatively with no problems (Figure 4). The patient resumed playing and coaching snooker at the elite level and reported making his largest break in several years.

**Case 4.** A 76-year-old patient with UCVA of logMAR 0.6 underwent uneventful phacoemulsification and implantation of a monofocal AcrySof SA60AT IOL. The patient's UCVA was logMAR 0.78 postoperatively, as her against-the-rule corneal astigmatism had increased from 1.50 D

**TABLE 1. POWER RANGES**

TABLE 1. POWER RANGES	
Sulcoflex aspheric	-10.00 to 10.00 D in 0.50 D increments
Sulcoflex toric	-6.00 to 6.00 D of sphere in 0.50 D increments, and 1.00 to 6.00 D of cylinder in 1.00 D increments
Sulcoflex multifocal	-3.00 to 3.00 D of sphere (including plano) with 3.50 D near add.




Figure 5. Case 4: Clear implants with (A) a gap between the IOLs. (B) The mark on the toric Sulcoflex IOL at 20° with no rotation.

preoperatively to 3.00 D postoperatively. After discussing all possible options, the patient opted for a toric Sulcoflex IOL, which was implanted in the sulcus without complications. On postoperative day 1, the patient's UCVA was logMAR 0.2, and, at 5 weeks postoperative (Figure 5), the patient was delighted with a UCVA of logMAR 0.17, improving to logMAR 0.1 with refraction of -0.50 -1.00 X 80°. No complications were noted at this visit and there was no rotation of the Sulcoflex toric lens.

**CONCLUSION**

In summary, piggybacking is a useful technique to correct residual ametropia. The Sulcoflex IOL can dramatically improve results of primary IOL surgery in many cases. As with all refractive procedures, appropriate patient selection and counseling, as well as proper preoperative measurements and intraoperative techniques, can result in excellent outcomes with minimal risk of complications. ■

*Mohammed I. Khan, MRCOphth, is a Specialist Registrar, Wales Deanery, United Kingdom. Dr. Khan states that he has no financial interest in the companies or products mentioned.*

*Mohammed Muhtaseb, FRCOphth, is a Consultant Ophthalmologist at Singleton Hospital, Swansea, and at i.Lase Cornea, Cataract and Refractive Clinic, London. Dr. Muhtaseb states that he is consultant to Rayner Intraocular Lenses Ltd. He may be reached at tel: +44 1792 285040; e-mail: m.muhtaseb@ilase.co.uk.*



- Gayton JL, Saunders VN. Implanting two posterior chamber intraocular lenses in a case of microphthalmos. *J Cataract Refract Surg.* 1993;19(6):776-777.
- Gayton JL, Saunders V, Van Der Karr M, Raanan MG. Piggybacking intraocular implants to correct pseudophakic refractive error. *Ophthalmology* 1999;106(1):56-59.
- Holladay JT, Gills JP, Leidlein J, Cherchio M. Achieving emmetropia in extremely short eyes with two piggyback posterior chamber intraocular lenses. *Ophthalmology* 1996;103(7):1118-1123.
- Akhaishi L, Tselikis PF. Primary piggyback implantation using the ReSTOR intraocular lens: case series. *J Cataract Refract Surg.* 2007;33(5):791-795.
- Mejia LF. Piggyback posterior chamber multifocal intraocular lenses in anisometropia. *J Cataract Refract Surg.* 1999;25(12):1682-1684.
- Donoso R, Rodriguez A. Piggyback implantation using the AMO Array multifocal intraocular lens. *J Cataract Refract Surg.* 2001;27(9):1506-1510.
- Masket S. Piggyback intraocular lens implantation. *J Cataract Refract Surg.* 1998;24(4):569-570.
- Shugar JK, Lewis C, Lee A. Implantation of multiple foldable acrylic posterior chamber lenses in the capsular bag for high hyperopia. *J Cataract Refract Surg.* 1996;22(Suppl 2):1368-1372.
- Shugar JK, Schwartz T. Interseudophakos Elshnig pearls associated with late hyperopic shift: A complication of piggyback posterior chamber intraocular lens implantation. *J Cataract Refract Surg.* 1999;25(6):863-867.
- Werner L, Mamilis N, Stevens S, et al. Interlenticular opacification: dual-optic versus piggyback intraocular lenses. *J Cataract Refract Surg.* 2006;32(4):655-661.