

# Correcting Refractive Surprises Following Cataract Surgery

Postsurgical refractive results can be enhanced with a supplementary IOL, such as the Sulcoflex.

BY MICHAEL AMON, MD

Given the availability of advanced IOL designs and modern surgical techniques, precise refractive results following cataract surgery and IOL implantation is a reasonable expectation.

Indeed, our patients are becoming increasingly informed about new technologies and surgical methods of refractive correction. In cases of refractive lens exchange (RLE), the patient demand for a near-perfect visual outcome is even higher than it is with our cataract patients.

Certainly, the advent of optical coherence biometry, which uses partially coherent light to measure the axial length of the eye along its visual axis and provides the surgeon with keratometry readings and anterior chamber depth measurements, has significantly increased refractive accuracy during cataract surgery. However, postoperative refractive surprises may still occur, albeit less frequently, for which a secondary surgical intervention is often indicated.

IOL power calculations for cataract patients who have previously undergone keratorefractive surgery are often less accurate than they are for patients who have not had refractive surgery. This is largely due to difficulties that may be encountered during the determination of corneal



Figure 1. The multifocal Sulcoflex IOL.

## TAKE-HOME MESSAGE

- Aspheric, multifocal, and toric supplementary IOLs are currently available.
- Power calculations for supplementary IOLs depend on the patient's current refraction, not preoperative measurements.
- Supplementary IOLs offer a safer, less traumatic option for pseudophakic ametropia or enhancing postrefractive results compared with IOL exchange.

refractive powers, such as using the wrong keratometry values. This is particularly true after myopic keratorefractive surgery because the corneal refractive powers may easily be overestimated. In many cases, this can lead to a hyperopic postoperative refractive outcome.

## OPTIONS

Several options are available for subsequent correction of refractive surprises, including prescription of spectacles or contact lenses, IOL exchange, keratorefractive surgery, or implantation of a supplementary IOL (ie, *poly-pseudophakia*).<sup>1-3</sup> Spectacles may not be the best option, especially for younger, more self-aware patients. Similarly, contact lenses are often inappropriate for older or infirm patients. Keratorefractive surgery may also not be the best solution because of the inherent risks associated with further corneal surgery. In many instances, such an option may be impossible or unavailable.

IOL exchange and supplementary IOLs, implanted in the ciliary sulcus anterior to the primary implant, can be easier and safer surgical options, especially when capsular changes have firmly fixated the primary implant within the capsular bag. Because IOL exchange may be associated

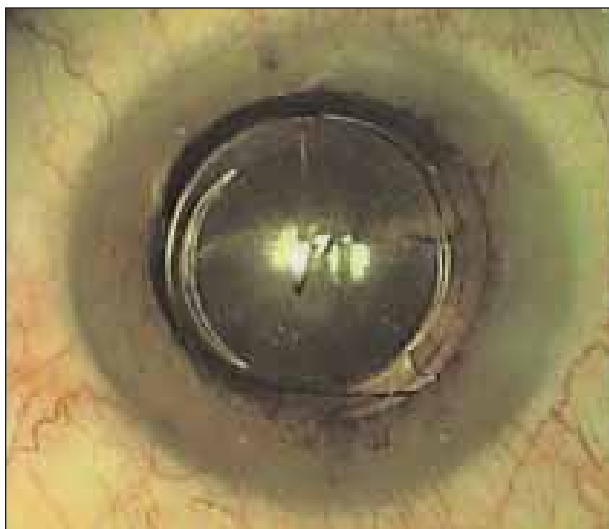


Figure 2. An intraoperative view of the toric Sulcoflex.

with increased risk of capsular rupture or zonular dehiscence with vitreous loss,<sup>4</sup> the implantation of a supplementary IOL may be the more acceptable option. If I have to correct refractive surprises after cataract surgery, I typically use supplementary IOLs. In this article, I discuss the advantages of this refractive correction method after cataract surgery.

### PREDICTABLE AND REVERSIBLE

One major advantage of polypseudophakia is predictability. When a postcataract-surgery refractive surprise is suggestive of a secondary intervention, there is often an underlying uncertainty as to whether the correct implant power was used in the primary procedure. If an IOL exchange is used in this situation, especially if the original power miscalculation is repeated, it can affect the refractive result—assuming that the primary implant was not mislabelled. Alternatively, the power calculation for the supplementary IOL depends solely on the patient's current refraction. If the surgeon chooses to perform an IOL exchange, he cannot be confident that the replacement IOL will be implanted in exactly the same plane as the original IOL. For these reasons, my choice is the supplementary IOL.

A further advantage of polypseudophakia is reversibility. Unlike the option of laser vision correction, the supplementary IOL may easily be explanted from the sulcus if necessary. Although in my series I have not removed a single implant, explanation could become necessary if the wrong implant is used, if the implant shows any damage, or if the patient wants to change his refraction for a second time.

### IOL CHOICE

Care must be exercised in choosing the supplementary

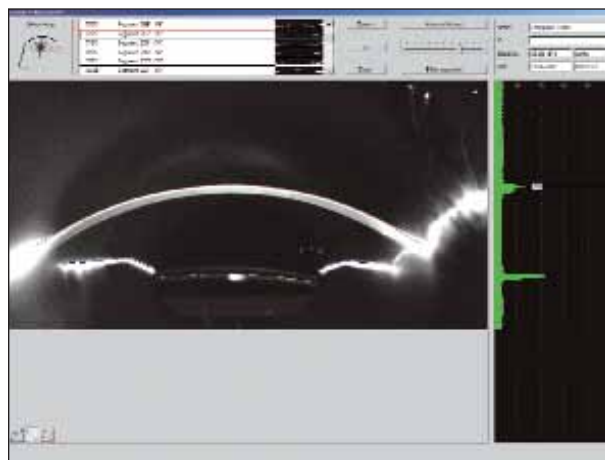


Figure 3. Scheimpflug picture demonstrating adequate iris-IOL and IOL-IOL distance.

IOL. IOLs designed primarily for in-the-bag placement are not appropriate for supplementary procedures because their performance dynamics differ considerably.<sup>5,6</sup>

Conventional uniplanar IOLs (ie, IOLs without posterior haptic angulation) can cause iris chafing and pigment dispersion<sup>7</sup> when piggybacked in the ciliary sulcus because contact with the iris may easily occur. In particular, these side effects are known to occur if uniplanar IOLs with relatively steep anterior surfaces are used. In addition to unwanted pigment adhesion to the implant surface, pigment dispersion may also increase the risk of intraocular pressure elevation and glaucoma.<sup>7</sup> This disadvantage is further compounded when conventional IOL designs are used in conjunction with higher powered primary implants because their relatively steeper anterior surfaces can cause contact between the IOLs, thereby increasing the likelihood of anterior vaulting of the secondary lens.<sup>8,9</sup> Therefore, a poor polypseudophakic refractive outcome may result. Any physical contact, especially with foldable or injectable IOLs, may cause deformation of the optic surfaces at the point of contact, resulting in a hyperopic shift and possible unwanted photopic effects.<sup>5</sup>

The Sulcoflex Pseudophakic Supplementary IOL (Rayner Intraocular Lenses, Ltd., East Sussex, United Kingdom) is an exciting development in IOL design, allowing piggyback implantation in pseudophakic eyes and offering precise refractive results after cataract surgery or RLE. Unlike conventional IOLs, the Sulcoflex was specifically designed for polypseudophakia with biomaterial attributes calculated to overcome the disadvantages of conventional IOLs.

This one-piece IOL is designed with a hydrophilic acrylic copolymer noted for its high uveal biocompatibility,<sup>10,11</sup> a factor important for IOLs specifically designed for ciliary sulcus placement. The 6.5-mm optic diameter, with an

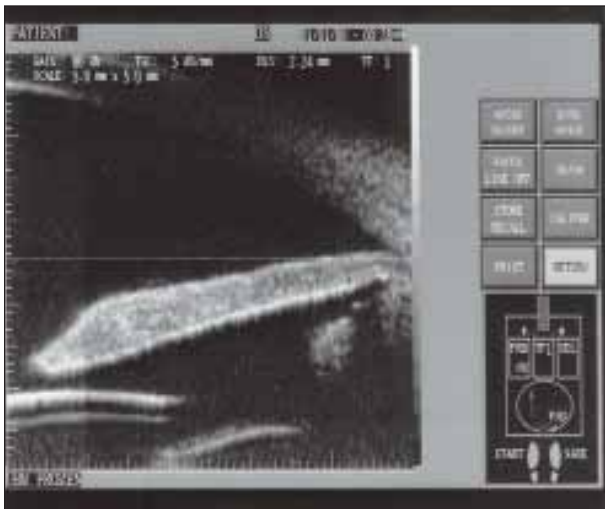

Figure 4. UBM demonstrating good iris-IOL distance.

anterior convex and posterior concave configuration, creates a perfect fit with the anterior convex surface of the primary IOL. The 12.5-mm haptics are posteriorly angulated with undulated edges to preclude IOL rotation, a factor particularly important for the postoperative refractive accuracy of a toric design. The haptic angulation is also effective in maintaining distance from the iris, thereby reducing the occurrence of pigment dispersion syndrome and optic capture.<sup>7</sup> As posterior capsular opacification is not a consideration with this design, the haptic and optic edges are rounded to reduce dysphotopsia. The Sulcoflex Pseudophakic Supplementary IOL is intended solely for ciliary sulcus placement; interlenticular opacification, seen when both IOLs are implanted in the bag,<sup>12-14</sup> is not a characteristic of this design.

These supplementary IOLs may be implanted simultaneously with the primary implant in special cases of patients with high hyperopia, myopia, or corneal astigmatism, or during a secondary implant procedure. They are available with aspheric monofocal, aspheric toric, and aspheric multifocal (refractive type) designs.

#### INDICATIONS FOR IMPLANTATION

Indications for the implantation of Sulcoflex Pseudophakic Supplementary IOLs are the correction of postsurgical pseudophakic and postkeratorefractive surgical ametropia, the correction of higher-order aberrations (obtained with the aspheric design), the correction of supplementary residual pseudophakic astigmatism (with the toric design), and for the correction of pseudophakic presbyopia (with the multifocal design). Especially in eyes with dynamic refraction, such as pediatric cases, keratoconus, silicone, and keratoplasty, the use of this IOL may be advantageous. Theoretically,

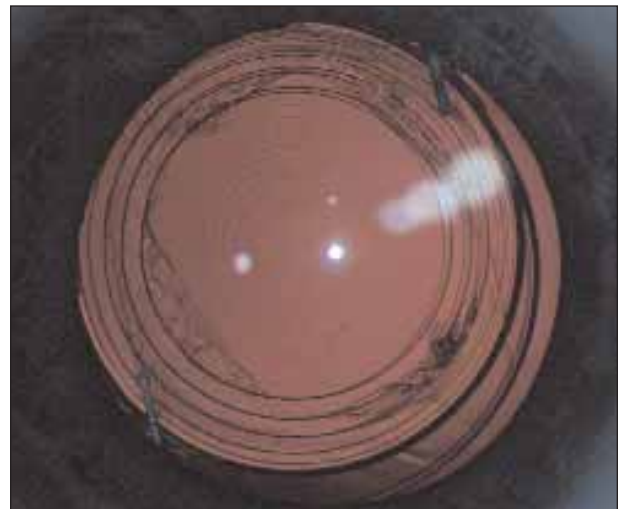


Figure 5. Monofocal Sulcoflex on a diffractive multifocal IOL.

pseudophakic dysphotopsia should also be minimized by use a secondary implant.

#### STUDY DESIGN, RESULTS

In a recent study, Sulcoflex monofocal aspheric or multifocal (Figure 1) models were implanted into the ciliary sulcus of pseudophakic eyes. All IOLs were implanted through a 3-mm clear corneal incision. After surgery, near and far UCVA and BCVA and IOP were assessed. Inflammation was measured with a laser flare/cell meter, and position and rotational stability of the IOL were regularly documented at all visits. Additionally, Scheimpflug photography and ultrasound biomicroscopy were performed.

Surgeries were performed without complication in all cases; at 1 year, no intra- or postoperative complications were detected, and emmetropia ( $\pm 0.25$  D) was achieved in all cases with stable refraction. Flare values were lower than the values measured after standard cataract procedures. Rotational stability and centration were excellent (Figure 2). IOP was within the normal range at all visits. No iris chafing was documented, and in all cases a good distance was observed between the iris and the Sulcoflex Pseudophakic Supplementary IOL (Figure 3). Similarly, a good distance was observed between the supplementary IOL and the primary implant (Figure 4).

In cases with the multifocal Sulcoflex version and in cases with a monofocal Sulcoflex and a multifocal primary IOL (Figure 5), all patients achieved spectacle independence.

In conclusion, the correction of pseudophakic ametropia, or the enhancement of postsurgical refractive results with the Sulcoflex Pseudophakic Supplementary IOL offers a safer, less traumatic option than IOL exchange. Because of its material and design, this supplementary IOL is well tolerated within the eye. ■

Michael Amon, MD, is a Professor and Head of the Eye Department at the Academic Teaching Hospital Barmherzige



Brüder Wien, Vienna, Austria.

Professor Amon states that he is a paid consultant to Rayner Intraocular Lenses, Ltd. He may be reached at tel: +43 676 605 68 38; fax: +43 1 211 21 1144; e-mail: amon@ augenchirurg.com.

1. Gayton JL, Sanders VN. Implanting two posterior chamber intraocular lenses in a case of microphthalmos. *J Cataract Refract Surg.* 1993;19(6):776-777.
2. Gills JP, Gayton JL, Raanan M. Multiple intraocular lens implantation. In: Gills JP, Fenzel R, Martin RG, eds. *Cataract Surgery: The State of the Art.* Slack; Thorofare, NJ; 1998:183-195.
3. Fenzl RE, Gills JP 3rd, Gills JP. Piggyback intraocular lens implantation. *Curr Opin Ophthalmol.* 2000;11(1):73-76.
4. Dagres F, Khan M, Kyle G, Clark D. Perioperative complications of intraocular lens exchange in patients with opacified Aqua-Sense lens. *J Cataract Refract Surg.* 2004;30(12):2569-2573.
5. Findl O, Menapace R, Georgopoulos M, Kiss B, Petternel V, Rainer G. Morphological appearance and size of contact zones of piggyback intraocular lenses. *J Cataract Refract Surg.* 2001 Feb;27(2):219-23.
6. Werner L, Shugar JK, Apple DJ, Pandey SK, Escobar-Gomez M, Visessook N, Evans BB. Opacification of piggyback IOLs associated with an amorphous material attached to interlenticular surfaces. *J Cataract Refract Surg.* 2000;26(11):1612-1619.
7. Masket S. Pseudophakic posterior iris chafing syndrome. *J Cataract Refract Surg.* 1986;12: 252-256.
8. Gayton JL, Sanders V, Van Der Karr M. Pupillary capture of the optic in secondary piggyback implantation. *J Cataract Refract Surg.* 2001;27(9):1514-1515.
9. Shugar JK, Schwartz T. Interpseudophakos Elschnig pearls associated with late hyperopic shift: a complication of piggyback posterior chamber intraocular lens implantation. *J Cataract Refract Surg.* 1999;25(6):863-867.
10. Abela-Formanek C, Amon M, Schild G, Schauersberger J, Heinze G, Kruger A. Uveal and capsular biocompatibility of hydrophilic acrylic, hydrophobic acrylic, and silicone intraocular lenses. *J Cataract Refract Surg.* 2002;28(1):50-61.
11. Richter-Mueksch S, Kahraman G, Amon M, Schild-Burgasser G, Schauersberger J, Abela-Formanek C. Uveal and capsular biocompatibility after implantation of sharp-edged hydrophilic acrylic, hydrophobic acrylic, and silicone intraocular lenses in eyes with pseudoexfoliation syndrome. *J Cataract Refract Surg.* 2007;33(8):1414-1418.
12. Gayton JL, Apple DJ, Peng Q, Visessook N, Sanders V, Werner L, Pandey SK, Escobar-Gomez M, Hoddinott DS, Van Der Karr M. Interlenticular opacification: clinicopathological correlation of a complication of posterior chamber piggyback intraocular lenses. *J Cataract Refract Surg.* 2000; 26(3):330-336.
13. Spencer TS, Mamalis N, Lane SS. Interlenticular opacification of piggyback acrylic intraocular lenses. *J Cataract Refract Surg.* 2002;28(7):1287-1290.
14. Trivedi RH, Izak AM, Werner L, Macky TA, Pandey SK, Apple DJ. Interlenticular opacification of piggyback intraocular lenses. *Int Ophthalmol Clin.* 2001;41(3):47-62.