

ARTICLE

Treatment of patients with cataract and high astigmatism by using toric intraocular lenses

J Vos MBChB(UFS), MMed(Ophth)(UFS)

Address for correspondence:

Suite 107, Pasteur Medical Centre,
Hospital Park, Bloemfontein,
South Africa
E-mail: japie@vosmail.co.za
Tel: 27 51 5226757

Abstract

Background and purpose: To determine whether the implantation of a toric intraocular lens following cataract surgery is effective in reducing pre-existing corneal astigmatism.

Methods: A consecutive case series of 84 patients with high refractive errors, especially high astigmatism, who were unsuited to Excimer laser surgery, underwent a standard phacoemulsification operation followed by the implantation of a T-flex toric IOL ((Rayner Intraocular Lens Limited, East Sussex, UK). The patients were followed up over a four-year period.

Results: Eighty-four eyes experienced a significant improvement in uncorrected visual acuity (UCVA). Seventy-six per cent of all eyes treated had a postoperative UCVA of 0.50 or better.

The average spherical equivalent in eyes without any other pre-existing ocular conditions improved from 4.9 D pre-operatively to 0.5 D postoperatively, while eyes with pre-existing ocular conditions improved from 5.7 D pre-operatively to 0.5 D postoperatively. The average cylinder improved from 4.0 D pre-operatively to 0.8 D postoperatively in patients without any other ocular conditions, and from 5.3 D pre-operatively to 1.6 D postoperatively in patients with pre-existing ocular conditions.

Conclusion: Toric IOLs provide good results in treating varying degrees of pre-existing corneal astigmatism in normal eyes as well as in eyes with pre-existing pathology.

Financial disclosures: The author does not have any financial interest in any of the products mentioned in this article.

Introduction

Astigmatic patients with pre-existing or keratoplasty-induced astigmatism, who undergo cataract surgery or refractive lens exchange with a standard monofocal IOL, are often disappointed with the outcomes. This is due to residual astigmatism which additionally requires spectacle correction, hard contact lenses or another surgical procedure.¹

Different procedures are in use to enhance the postoperative optical quality of patients after cataract surgery, and simultaneously correct corneal astigmatism.² These include spectacle correction, rigid gas permeable contact lens, limbal relaxing incisions, refractive surgery and IOL implantation.

In cases where the astigmatism is high, spectacle correction, limbal relaxing incisions and refractive surgery may not be able to correct all of the astigmatism.

While a rigid gas-permeable contact lens may provide good visual acuity results in treating astigmatism, patient dissatisfaction with this procedure is high. This is due in part to the initial discomfort patients experience in wearing these lenses, as well as their preference for a permanent treatment like an IOL.³

Toric IOLs have shown good rotational stability and good functional results, and are therefore an excellent alternative for highly astigmatic eyes.⁴ While the focus of cataract surgery is the correction of aphakia, today's techniques and implants offer surgeons the opportunity to individualise the postoperative astigmatism of patients and thus increase overall patient satisfaction.¹

The objective of this study was to review a series of highly astigmatic cataract patients who were implanted with toric IOLs over a four-year period, in order to establish the merit of toric IOLs in correcting both the sphere and the cylinder.

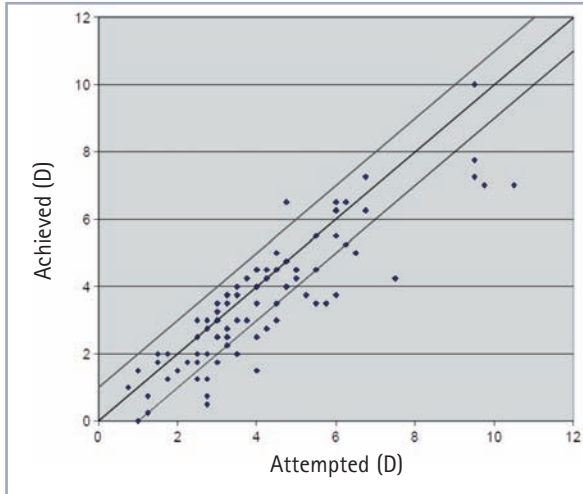


Figure 1: Attempted vs achieved cylinder correction

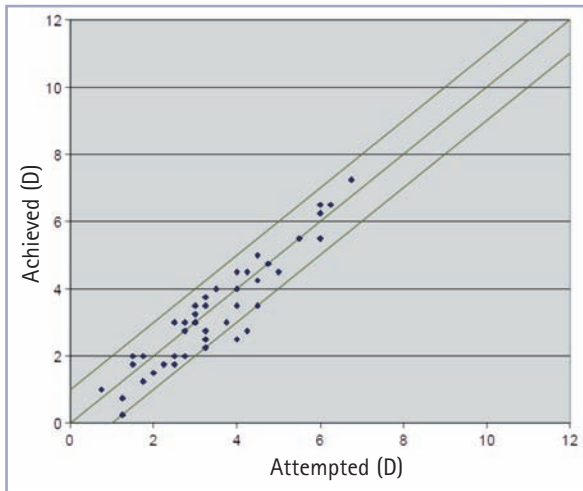


Figure 2: Attempted vs achieved cylinder correction (normal)

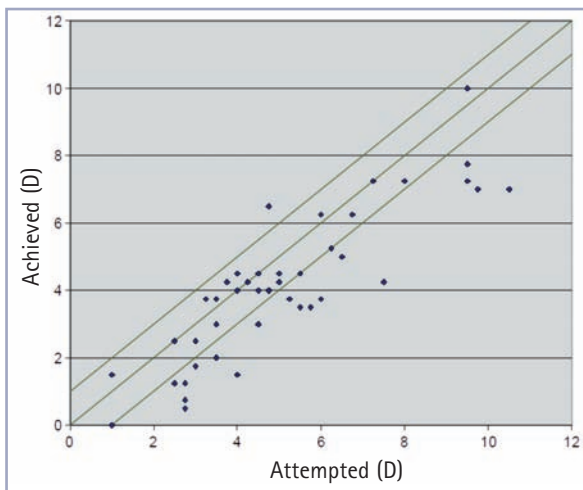


Figure 3: Attempted vs achieved cylinder correction (other)

Materials and methods

This study was a retrospective analysis of a consecutive case series of patients implanted with a toric IOL over a four-year period. The results of 84 cataract patients aged between 30 and 81 years, with high refractive errors, who were not suitable for Excimer laser surgery, were analysed. All patients were implanted with the Rayner acrylic hydrophilic T-flex toric IOL (Rayner Intraocular Lens Limited, East Sussex, UK) by the same surgeon (JdTV).

The pupil was dilated in all the cases, using Cyclomydril drops (Alcon Laboratories, Inc., Texas, USA). The patient's refraction was combined with the corneal K readings, and two corneal markings were made on the limbus with a YAG laser (Alcon Laboratories Inc., Texas, USA) to ensure proper alignment of the IOL. The IOL axis of the lowest dioptric power was marked and aligned with the axis of the highest power on the patient's cornea.

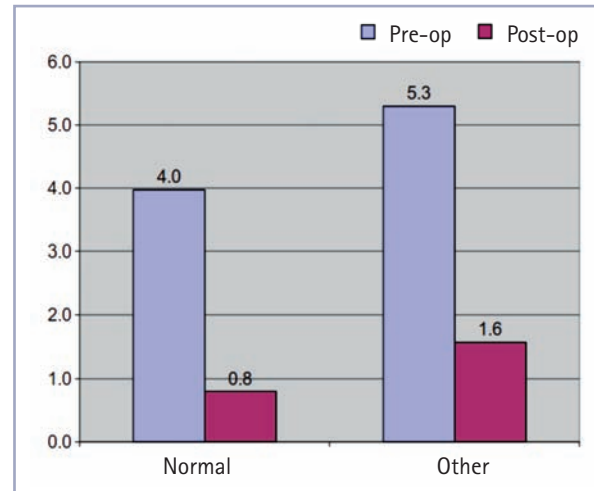


Figure 4: Average cylinder pre-op vs postop, ordered by pathology

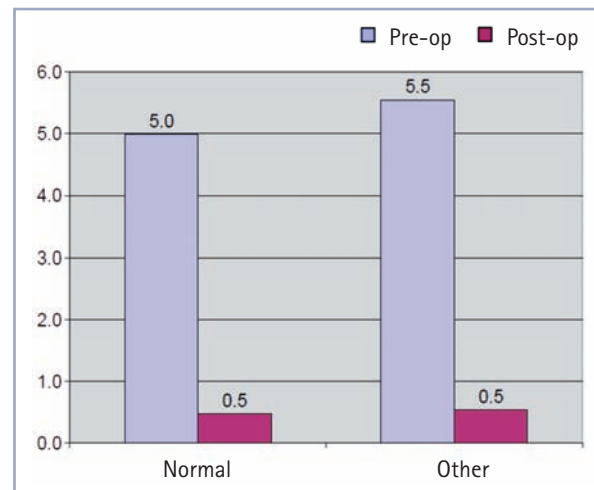


Figure 5: Average SE pre-op vs postop ordered by pathology

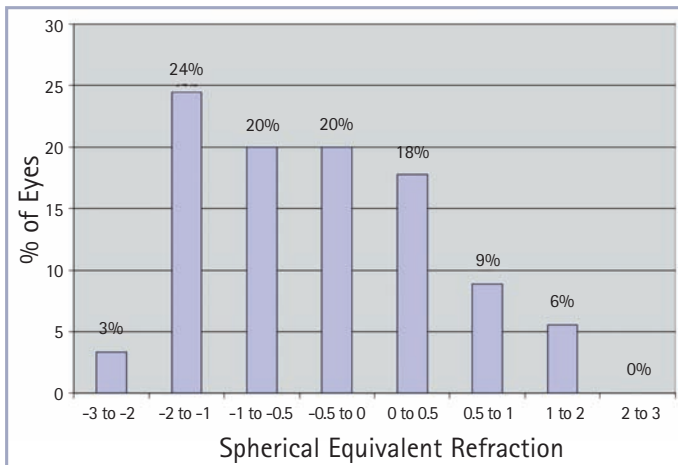


Figure 6: Distribution of SE postop (%)

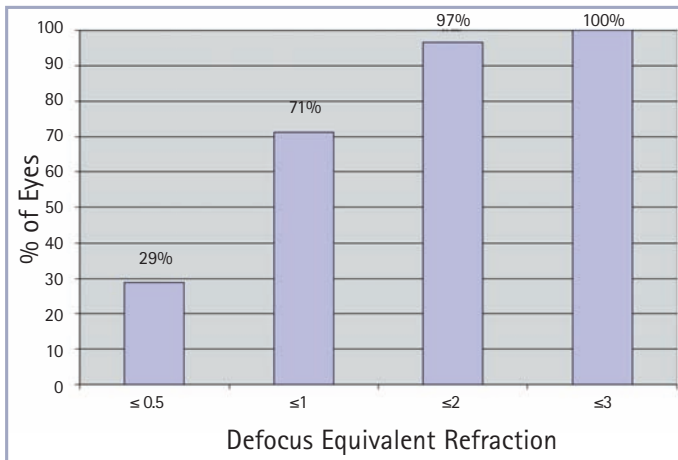


Figure 7: Cumulative distribution postop of defocus equivalent refraction

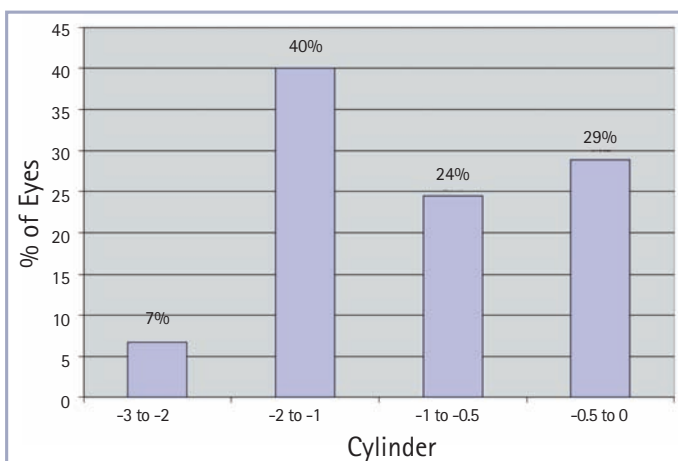


Figure 8: Distribution of cylinder postop (normal)

A 3.2 mm temporal clear corneal incision was made with a calibrated knife to perform the phacoemulsification and extract the cataract. Ocucoat (Bausch & Lomb, NY, USA) viscoelastic solution was injected and a continuous curvilinear capsulorrhexis (CCC) with a diameter of approximately 5.0 mm was created with a 26-gauge

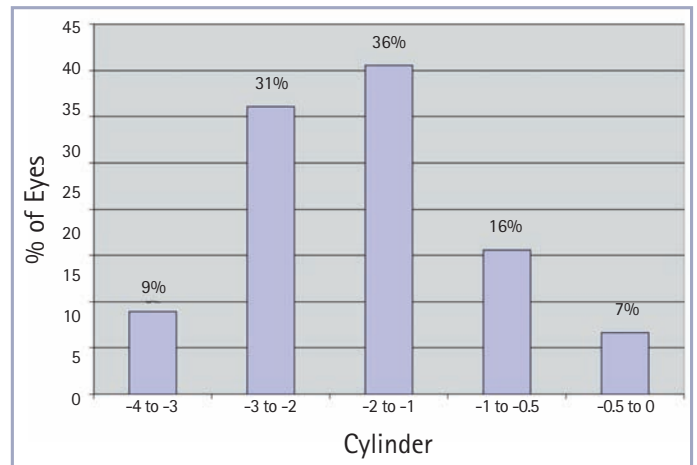


Figure 9: Distribution of cylinder postop (other)

bent needle. After hydrodissection, bimanual phacoemulsification was performed using the Infinity phacoemulsification system (Alcon Laboratories, Inc., Texas, USA). Irrigation/aspiration (I/A) was performed. Cortical remnants and the viscoelastic were removed with a 45-degree angled I/A tip with a diameter of 1.8 mm. The capsular bag was filled with the viscoelastic and the IOL was inserted into the capsular bag using forceps. Through clockwise rotation using the corneal axis markings, the torus (cylinder) was positioned on the anterior surface of the optic and the Amon-Apple Enhanced Square Edge on the posterior surface. Finally, the wound was hydrated.

T-flex toric IOLs are particularly useful for those cataract patients where incisional methods would provide inadequate astigmatic correction.⁵ The T-flex ensures precise surgical results, especially in severe astigmatic patients. Unlike plate-haptic and multi-piece toric IOLs, T-flex toric IOLs have inherent rotational stability.

Inclusion criteria

Cataract patients with corneal astigmatism higher than 2 D and corneas too thin to perform refractive laser surgery were included in the study.

Of the 84 eyes, 45 (count N = 45) eyes had no pre-existing ocular pathology. The remaining 39 eyes had ocular pathology including: penetrating keratoplasty (count PKP = 18); keratoconus (count C = 14); 4 eyes had previously undergone radial keratotomy (count RK = 4); optic neuritis (count ON = 2) and early stage age-related macular degeneration (count SMD = 1).

Complications

In two eyes the CCC were not intact; however, the posterior capsules were intact and the lens was placed with the optic mainly inside the bag and good stability.

Results

All eyes experienced a significant improvement in UCVA; 64 of 84 eyes (76%) had postoperative UCVA of 0.5 or better whereas pre-operatively only one eye had UCVA of 0.5 or better.

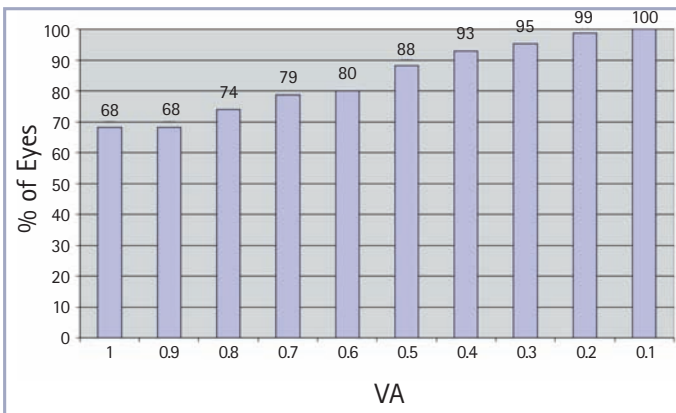


Figure 10: Cumulative distribution pre-op BCVA

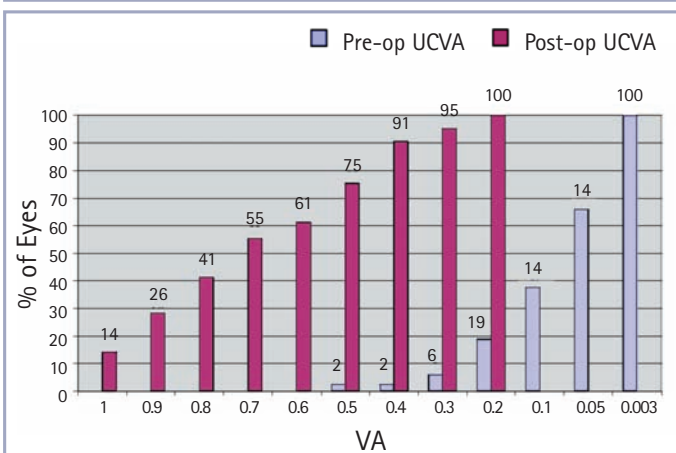


Figure 11: Cumulative distribution pre-op and postop UCVA

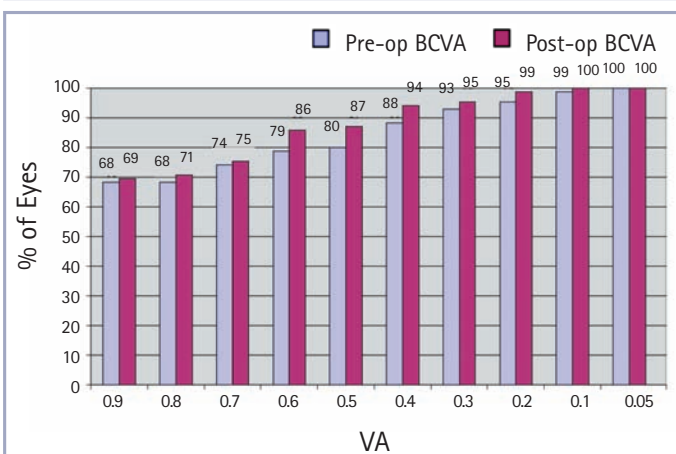


Figure 12: Cumulative distribution pre-op and postop BCVA

Of the eyes with no pre-existing pathology, 37 of the 45 eyes (82%) improved to UCVA of 0.5 or better, whereas pre-operatively none of these eyes had UCVA of 0.5 or better.

64 of 84 eyes (76%) had postoperative UCVA of 0.5 or better whereas pre-operatively only one eye had UCVA of 0.5 or better

Discussion

It is a known fact that larger astigmatism of up to 30 D can be corrected using a toric IOL.¹ The results of this study demonstrate that toric IOL implantation following cataract surgery effectively treats varying degrees of astigmatism. The visual results are favourable and the refractive target predictability is high.

The average cylinder results of patient eyes in our study improving from 4.0 D pre-operatively to 0.8 D postoperatively, correlate with those of another study conducted by Dardzhikova A *et al*,⁶ to assess the visual outcomes of toric IOL implantation for astigmatic correction in cataract patients. Here, the mean refractive cylinder of the 111 eyes improved from -1.25 D pre-operatively to -0.32 D postoperatively.

The unique Amon-Apple Enhanced Square Edge design of the T-flex toric IOL, reduces posterior capsular opacification (PCO) by creating a physical barrier to cell migration. It has a low YAG rate and offers greater customisation options with a sphere range of -10 D to $+35$ D and a cylinder range of $+1$ D to $+11$ D. This is especially useful when treating patients with varying degrees of refractive errors where one can effectively treat a patient's pre-operative astigmatism and increase overall patient satisfaction.

The T-flex achieved good visual outcomes because of the absence of rotation in lenses designed with Rayner's patented AVH technology.

Compared to incisional techniques, toric implants provide better predictability and precision and suffer less from regression as they have inherent rotational stability, which is important as good visual acuity is directly related to IOL rotational stability and refractive predictability.^{2,4}

The satisfactory results of this consecutive case series, achieved with the toric IOL, demonstrates that we can consider implantation of this lens as a procedure with the potential for safe, predictable and effective correction of astigmatic errors in pseudophakic eyes.

References

1. Auffarth GU, Rabsilber TM. Toric IOLs after cataract surgery and refractive lens exchange. *Ophthalmologe* 2007 Dec;104(12):1024-31.
2. Kohnen T, Klaproth OK. Correction of astigmatism during cataract surgery. *Klin Monbl Augenheilkd.* 2009 Aug;226(8):596-604. Epub 2009 Aug 11.
3. Ozkan B, Elibol O, Yuksel N, *et al*: Why do patients with improved visual acuity drop out of RGP contact lens use? Ten-year follow-up results in patients with scarred corneas. *Eur J Ophthalmol* 2009 May-Jun;19(3):343-7.
4. Correia RJ, Moreira H, Netto SU, *et al*. Visual performance after toric IOL implantation in patients with corneal astigmatism. *Arq Bras Ophthalmol* 2009 Sep-Oct;72(5):636-40.
5. Mendicute J, Irigoyen C, Ruiz M, *et al*. Toric intraocular lens versus opposite clear corneal incisions to correct astigmatism in eyes having cataract surgery. *J Cataract Refract Surg* 2009 Mar;35(3):451-8.
6. Dardzhikova A, Shah CR, Gimbel HV. Early experience with the AcrySof toric IOL for the correction of astigmatism in cataract surgery. *Can J Ophthalmol* 2009 Jun;44(3):269-73.